

CONGENITAL POPLITEAL WEBBING IN SIBLINGS

A Report of Two Cases

RANDELL CHAMPION and J. C. F. CREGAN, MANCHESTER, ENGLAND

Severe congenital web formation in the limbs and neck is uncommon, and often hereditary. Shun-Shin (1954), reporting a large Mauritian family with congenital antecubital webbing in three generations, made a comprehensive review of the literature on this subject in general, and the two siblings with extensive popliteal webbing described in this paper resemble the patients reported by Wolff (1889) (one knee only); Kopits (1937) (both knees affected in four patients); Edwards (1938) (both knees affected in one patient); and Aberle-Horstenegg (1938) (both knees affected in one patient).

CASE REPORTS

Case 1—A first child of normal parents was admitted to the Duchess of York Hospital for Babies at the age of one week. The sex was indeterminate, as the genitalia showed both male and female characteristics, but was later determined to be female. She had a cleft of the soft palate and two congenital sinuses of the mucous membrane of the lower lip. She had skin webs extending from the region of the ischial tuberosities to the heels, the knees being held flexed 100 degrees. The skin of the webs appeared normal, but at the free margin of each web a hard, inelastic subcutaneous cord two millimetres thick extended from the ischial tuberosities to the inner side of the insertions of the calcaneal tendons, causing a rigid inversion of the heels and feet (Fig. 1). The toes were maldeveloped; only three toes were present on each foot, one being a true hallux and one a syndactyl of two digits; four metatarsals were present.

As it seemed most unlikely that the hard subcutaneous cord would ever stretch, operation was undertaken on the right leg when the child was two weeks old. The skin web of the popliteal fossa, extending from the ischial tuberosity to the heel, was adjusted by Z-plasty extending from the limits of the webbing. When the skin was reflected there was a satisfactory exposure of the underlying structures. The subcutaneous fibrous cord was detached from the ischial tuberosity and from the fibrous tissue above the heel, and the loose fibromuscular and fatty tissue of the web dissected out. The sciatic nerve and its branches were found lying free in the length of the web, half-way between the free edge and the apex, and well superficial to the normal muscular structures. The popliteal vessels were normally situated deep in the popliteal space. The hamstrings and calf muscles appeared normal except for some merging of their fibres with the fibromuscular layers of the web, both medially and laterally (Fig. 3). These fibromuscular septa joined the cord at the free edge of the web, forming a thin hood over the sciatic nerve, so that the sciatic nerve may be said to have been covered by muscular tissue. The septa were excised, but the knee could then be straightened only by 30 degrees. The posterior tibial branch of the sciatic trunk was divided at the ankle to minimise the bowstring tension on the sciatic nerve; it was supposed that this tension might produce a high sciatic palsy while the deformity was later being corrected. The Z-plasty was closed in the usual manner. Healing was uneventful, apart from a small area of skin necrosis at the apex of the lower flap which necessitated supplementary skin grafting. After the operation 70 degrees of contracture remained, from capsular and musculo-tendinous resistance.

A similar operation was carried out on the left leg at the age of four months, the anatomical findings and operative steps being the same except that the posterior tibial nerve was not divided.

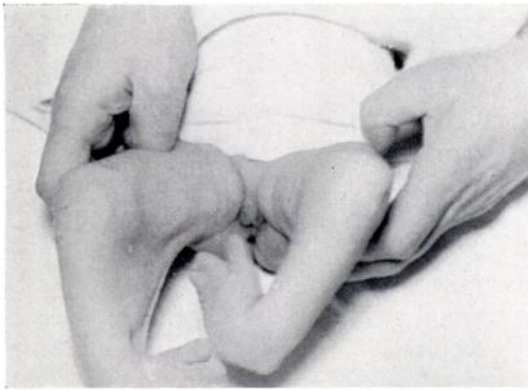

FIG. 1

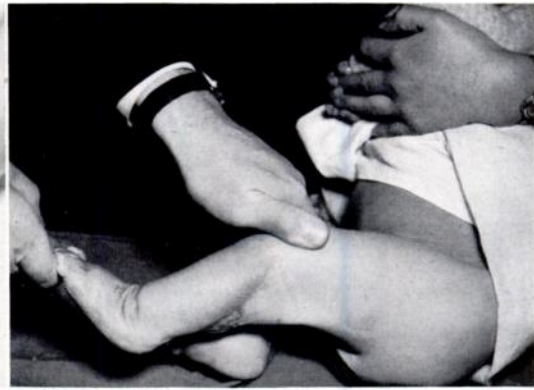

FIG. 2

Case 1. Figure 1—The webbing is seen to extend the whole length of the leg. Figure 2—One year after operation the extension of the knee lacks only 20 degrees.

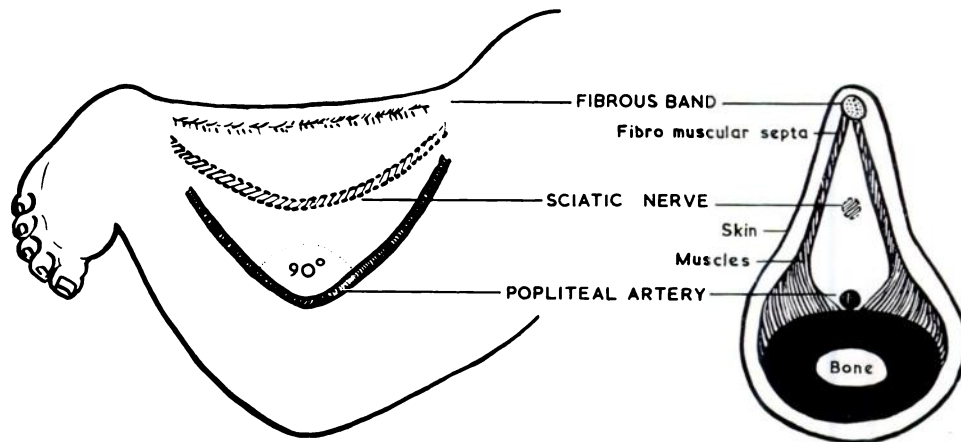


FIG. 3

A diagrammatic illustration of the findings at the operations in the two patients.

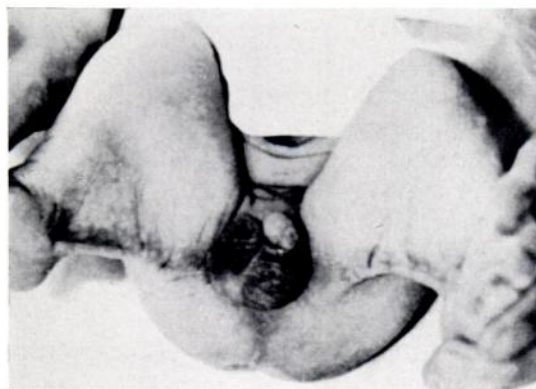


FIG. 4

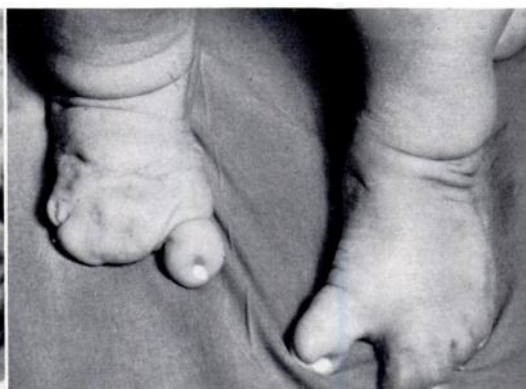

FIG. 5

Case 2. Figure 4—The webbing and the fibrous band is clearly shown. Figure 5 shows the deformity of the feet in the same infant.

After the operations, correction of the flexion deformities of the knees and feet was easily effected by serial moulded plasters and later by physiotherapy. At six months of age the cleft in the soft palate was closed by the standard two flap V-Y method. The sinuses of the mucous membrane of the lower lip were excised a month later.

The child is now two years old and can stand unaided. Active and passive extension of the knees is within 20 degrees of normal (Fig. 2). There is no paralysis in the left leg, and it is plain that, unfortunate as the position of the nerves appears at operation, they can accommodate themselves to the gradual corrective extension of the knees.

Case 2—One year later a second child, a boy, was born to the same parents (Fig. 4). The same deformities in the mouth, legs and feet were present as had been present in his sister, except that the left foot had one hallux and two pairs of syndactylous toes, and the right foot had one hallux and no other toes (Fig. 5). The treatment was also the same; operation was undertaken between the fourth and sixth months of life, the posterior tibial nerve being left intact in both legs. The gain in passive knee extension on the operation table was again only about 30 degrees from the initial 100-degree contracture, but a steady improvement has been obtained in the range with simple stretching and physiotherapy. Nine months after operation passive extension is now 45 degrees from full, and is still increasing in both knees. There is no evidence of weakness in the muscles supplied by the sciatic nerve.

SUMMARY

The early management of bilateral congenital popliteal webbing in a brother and sister is described. There was no familial history of webbing, but the maternal grandfather had a hare-lip. Although the sciatic nerve is so unfavourably placed in the web, correction of the flexion deformity can apparently be carried out safely after plastic repair of the skin by Z-plasty and excision of the fibrous web cord alone, without causing a traction paralysis. These cases appear to be unique in that the patients are siblings of different sex with identical congenital abnormalities of bilateral webbing, cleft palate and fistulae of the mucous membrane of the lower lip.

Our thanks are due to the Department of Medical Illustration, Wythenshawe Hospital, for their help.

REFERENCES

- ABERLE-HORSTENEGG, W. (1938): Flughautbildung zwischen Ober- und Unterschenkel mit abnormer Muskelbildung (M. ischio-suralis). *Zeitschrift für Orthopädie und ihre Grenzgebiete*, **67**, 21.
- EBSTEIN, E. (1918): Über das Vorkommen der Flughautbildung beim Menschen. *Dermatologische Wochenschrift*, **67**, 607.
- EDWARDS, L. M. (1938): Webbing of Lower Limbs, Associated with Congenital Bilateral Contractions of Flexor Muscles of Elbow and Wrist. *Proceedings of the Royal Society of Medicine (Clinical Section)*, **31**, 1,053.
- KOPITS, E. (1937): Die als "Flughaut" bezeichneten Missbildungen und deren operative Behandlung. (Musculo-dysplasia congenita.) *Archiv für Orthopädische und Unfall-Chirurgie*, **37**, 539.
- SHUN-SHIN, M. (1954): Congenital Web Formation. *Journal of Bone and Joint Surgery*, **36-B**, 268.
- WOLFF, J. (1889): Über einen Fall von angeborener Flughautbildung. *Archiv für klinische Chirurgie*, **38**, 66. (Quoted by Ebstein 1918.)