

## SOLITARY MYELOMA OF THE CLAVICLE WITH LONG SURVIVAL AFTER TOTAL EXCISION

### Report of a Case

J. McLAUCHLAN, ABERDEEN, SCOTLAND

A fifty-year-old man was admitted on May 9, 1947, having twisted his right arm eleven months before. He had felt a sudden pain in the right shoulder which passed off, only to recur nine months later when he wrenched the shoulder with a heavy weight. At this time he noticed a swelling over the middle of the clavicle. Examination confirmed the presence of a large irregular swelling involving the mid-shaft of the right clavicle. Movements of the shoulder were full and painless. There were no other abnormal clinical findings.

*Investigations*—Radiological skeletal survey was normal except for the right clavicle, which showed the typical appearance of a myeloma of bone with a pathological fracture (Fig. 1). The plasma proteins were normal chemically and electrophoretically, and the urine showed no Bence Jones protein. A full blood count was normal and the Wassermann reaction was negative.

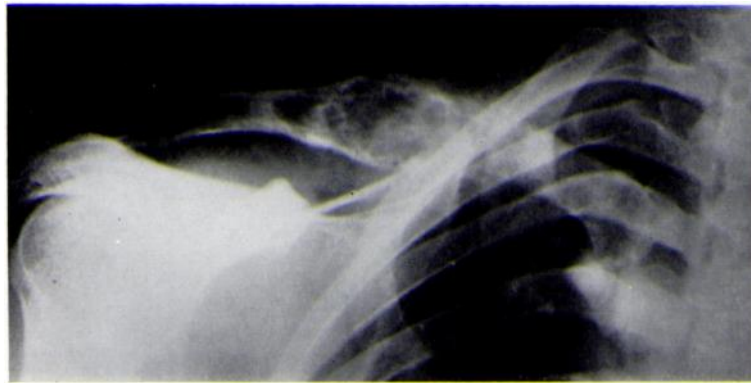


FIG. 1  
Radiograph showing lesion of right clavicle.

Biopsy provided fragments consisting almost entirely of masses of cells with the morphological characteristics of plasma cells. These were mostly well differentiated with intense pyroninophilia, but occasional multinucleate forms and cells with irregular nuclei were present. Mitotic figures were scanty. The features were those of a plasmacytoma.

*Operation and progress*—On May 17, 1947, the clavicle was completely excised extraperiosteally. The patient made an uneventful recovery and returned to light work within two months.

The excised length of clavicle showed the same histology as the biopsy fragments (Figs. 2 and 3). The tumour was found to end abruptly and did not appear to infiltrate the adjacent marrow.

The patient was seen regularly; the plasma proteins, urine, blood and skeletal survey remained normal. When last seen he was fit and well some twenty-four years after excision of the clavicle.

### COMMENT

Most so-called solitary myelomas become multiple if followed for long enough. Dissemination can occur many years after the initial discovery of the "solitary" lesion. Griffiths (1966) found reports of sixty-seven cases of alleged solitary myeloma. Most of the cases

considered to be permanently solitary were either incompletely described or the follow-up was short. He suggested strict criteria before a myeloma could be considered to be solitary: there should be 1) survival over twelve years without dissemination, and 2) negative histology of every bone at necropsy. He believed that there were very few instances in which the focus remained solitary indefinitely and behaved as a single tumour: indeed he accepted only eight of the sixty-seven cases that he reviewed as cases of truly solitary myeloma.

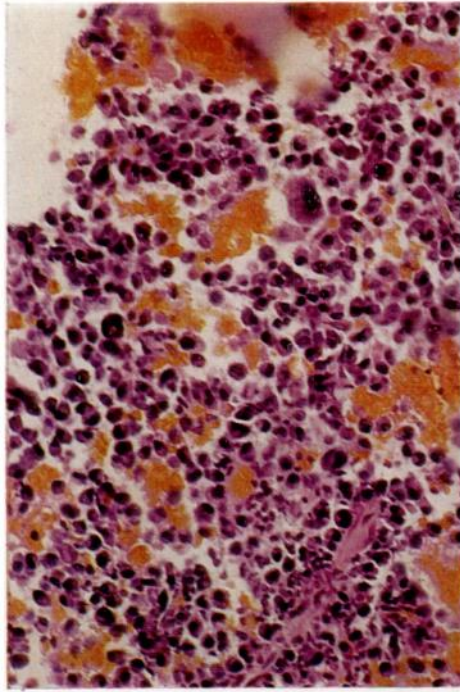


FIG. 2

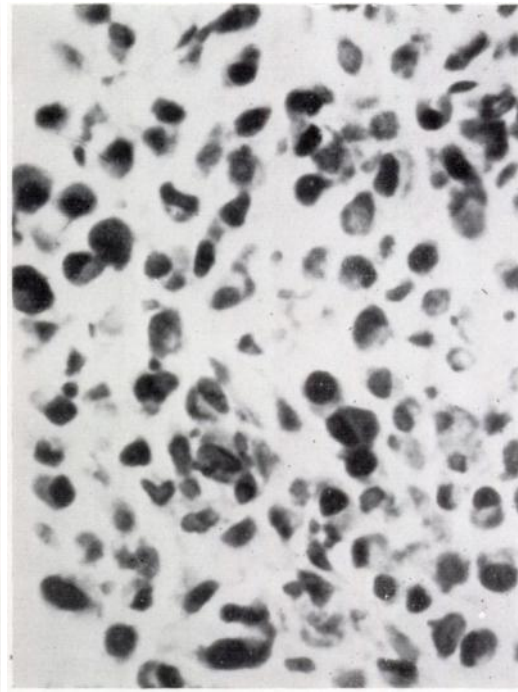


FIG. 3

Figure 2—Photomicrograph of lesion in right clavicle. Figure 3—Higher power photomicrograph. The tumour is composed predominantly of well differentiated plasma cells.

It has been the experience of most that the diagnosis of solitary myeloma usually cannot be upheld after full investigation including a skeletal survey and an adequate study of the sternal marrow and plasma proteins. The disease is one of known long survival even without eradication of the first focus to be discovered, and it is not unknown for dissemination to be delayed for as long as ten years after the diagnosis was made.

#### SUMMARY

1. A case of solitary myeloma of the clavicle is reported. The patient remained well, without signs of dissemination, twenty-four years after excision of the clavicle.
2. Solitary myeloma is rare; the diagnosis depends upon thorough investigation and prolonged follow-up.

I would like to thank Professor A. M. Rennie for allowing me to publish this case and Dr P. V. Best for help with the pathology.

#### REFERENCES

GRIFFITHS, D. LI. (1966): Orthopaedic Aspects of Myelomatosis. *Journal of Bone and Joint Surgery*, **48-B**, 703.