

# HUMAN TAILS

J. A. BAR-MAOR, K. M. KESNER, J. K. KAFTORI

*From the Department of Paediatric Surgery and the Department of Diagnostic Radiology,  
Rambam University Hospital, Haifa*

**Two children and one infant with a "human tail" are presented. The patho-embryology of this medical curiosity is briefly discussed. Treatment is usually unnecessary but resection of part of the coccyx together with the "tail" may become indicated by coccygodynia or for aesthetic reasons.**

A "human tail" is ill-defined. Reports in the literature describe soft-tissue projections in the coccygeal region (Parsons 1960; Lundberg and Parsons 1962; Fára and Smahel 1973): these probably represent a persistence of the embryonic tail, the non-chondrified lower coccygeal segments (Parsons 1960). Reports of such cases in the last century led to the classification by Bartels (1883) who described five types of rudimentary caudal appendages in man: three of these are variations of a "soft" tail presumably arising from the embryonic tail, the fourth is a bony tail caused by hypertrophy of the sacrococcygeal vertebrae and the fifth is a true animal tail containing additional vertebrae.

In the past three years three young children with "tails" have been seen.

## CASE REPORTS

**Case 1.** A 10-year-old Arab boy arrived at our Outpatient Department in 1977 complaining of pain in the coccygeal region. This had first been noticed some years previously but had become worse and was particularly severe when he was sitting on hard surfaces. He was fully continent of both urine and faeces. There was no history of injury, operation or illnesses other than those commonly occurring in childhood.

On examination, he was seen to be a healthy, well-developed child. Systematic examination was normal and there was no neurological deficit. On inspection, there was no perineal abnormality but on rectal examination the posterior bony wall was found to be markedly flexible and passive movement, particularly of the tip, caused the patient great discomfort.

A lateral radiograph of the lower vertebral column showed the normal number and configuration of lumbar and sacral vertebrae but there was a very prominent coccyx measuring 8.5 centimetres in length and consisting of five well-developed vertebrae. Anteroposterior

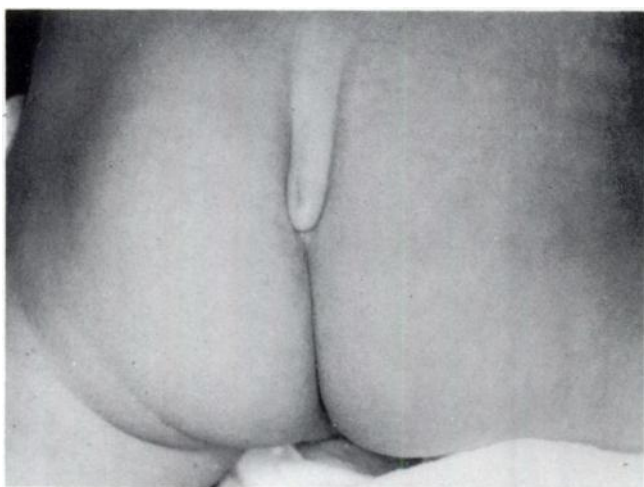


Fig. 1

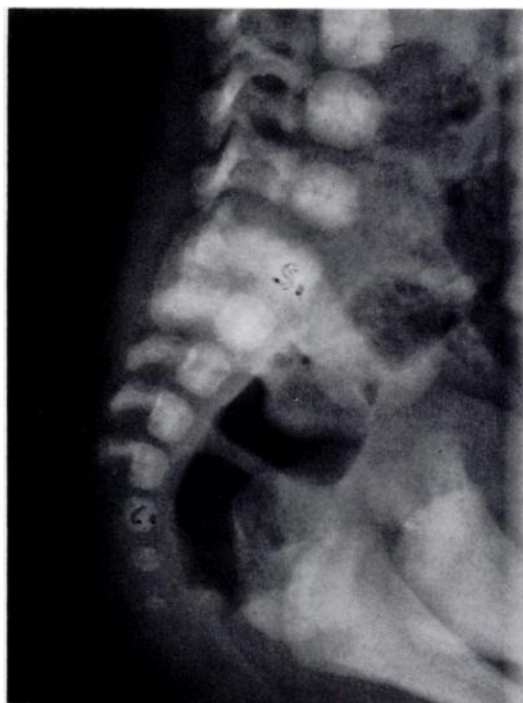

Fig. 2

Case 2. Figure 1—"Human tail" formed of coccygeal vertebrae and soft tissue. Figure 2—Lateral radiograph of the sacrum and three well-developed coccygeal vertebrae.

J. A. Bar-Maor, MD, FACS, Chief, Department of Paediatric Surgery  
K. M. Kesner, MB, ChB, Junior Registrar, Department of Paediatric Surgery  
J. K. Kaftori, MD, Director of Ultrasound Unit, Department of Diagnostic Radiology  
Requests for reprints should be sent to Dr J. A. Bar-Maor.

} Rambam University Hospital,  
Technion, Faculty of Medicine,  
Haifa, Israel.

radiographs of the pelvis showed a spina bifida of the first sacral segment but an otherwise normal sacral configuration. The prominent coccygeal vertebrae were again in evidence.

Partial excision of the coccyx was considered but not performed because the parents believed that the symptoms were not severe enough to warrant operation.

**Case 2.** Two years later, in 1979, a three-month-old Jewish baby was referred to our Outpatient Department because of a "tail" above the anus. On examination there were no pathological findings except a soft protrusion in the coccygeal region (Fig. 1). A lateral radiograph of the lower vertebral column showed three well-developed coccygeal vertebrae (Fig. 2).

For aesthetic reasons the infant was operated on and the protrusion together with part of the coccyx excised. Progress after operation was uneventful.

**Case 3.** One month later, a six-year-old girl came to our Outpatient Department with the same anatomical and radiographic findings (Fig. 3). Since she has no pain nor any cosmetic complaint she remains under observation, without surgical intervention, for the time being.

## DISCUSSION

### Development of the coccyx

Somite formation begins in the embryo soon after the twenty-first day (Williams, Wendell-Smith and Treadgold 1966). Reiter (1944) found that the greatest number of somites were seen at an embryonal length of seven millimetres (the fifth week) when he noted a total of 42: five occipital, seven cervical, 12 thoracic, five lumbar, five sacral and eight coccygeal. The somitic mesoderm extends medially to envelop the notochord and form the primitive mesenchymal vertebrae known as blastemal vertebrae (Williams *et al.* 1966). Reiter found that all eight coccygeal segments developed into blastemal vertebrae.

Centres of chondrification appear in the blastemal vertebrae about the sixth week, the notochord degenerates and the vertebral column takes over as the axial supporting structure (Williams *et al.* 1966). Chondrification centres do not appear in the lowest coccygeal blastemal vertebrae. As cartilage develops in the upper coccygeal region, the lowest segments disappear. By the eighth week, when the embryo measures 30 millimetres, the anatomy is almost that of the adult: the eighth, seventh and sixth coccygeal segments have disappeared and the fifth and fourth are in a process of reduction involving the loss of recognisable vertebral processes (Reiter 1944).

Each typical vertebra is ossified from three primary centres: one in each half of the vertebral arches and one in the body. Each segment of the coccyx, however, is ossified from only one primary centre (Gray's Anatomy 1967). The centre for the first segment appears about birth. The remaining segments ossify at widely separated intervals up to the twentieth year or later, but the specific times are not known. The normal coccyx is a small bone, triangular in shape and usually consisting of four rudimentary vertebrae fused together; but the number may be increased to five or reduced to three (Gray's Anatomy 1967).

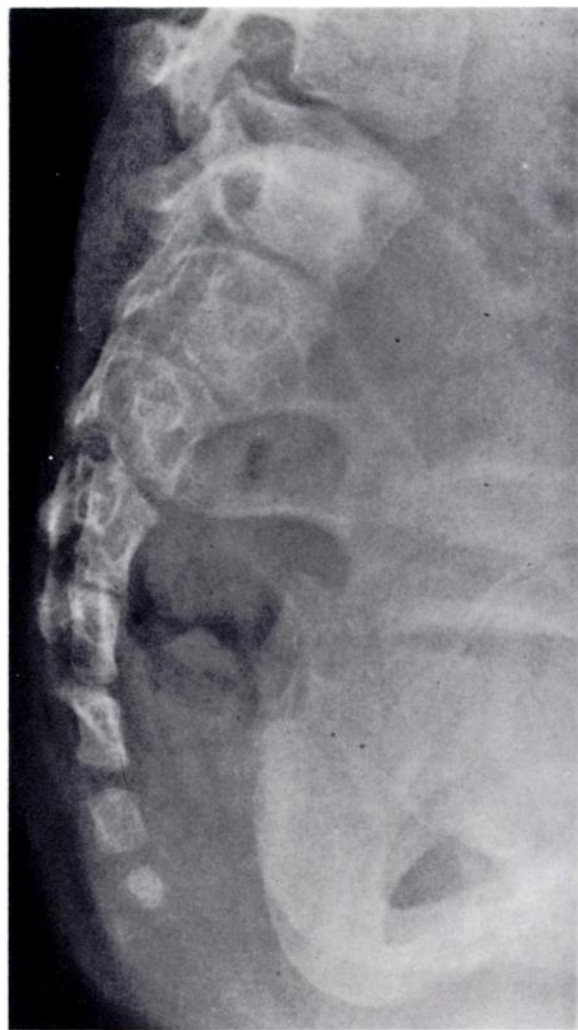

Fig. 3

Case 3. Lateral radiograph of the sacrum and three well-developed coccygeal vertebrae.

The development of the coccygeal "tail" in our patients can be explained as follows. Somite formation was normal and all eight coccygeal segments developed blastemal vertebrae. The eighth, seventh and sixth segments disappeared as normal. Each of the remaining coccygeal vertebrae developed primary centres of chondrification as in typical vertebrae (Parsons 1960): in the first patient there were five vertebrae, in the second and third patients there were three. Ossification occurred as in typical vertebrae from three primary centres, and it is likely that these centres were already present by the third month *in utero*.

### On human tails

Our first patient had no obvious coccygeal protuberance, but the coccygeal anomaly was well evident on radiographs as a tail-like structure and was the cause of his coccygodynia. This anomaly could be described in Bartels' traditional classification as "a bony tail caused by hypertrophy of the sacrococcygeal vertebrae". Our second and third patients had almost similar radio-

graphic findings, but in addition they had soft protuberances.

Miller (1881) reported the case of an Army officer who had an elongated coccyx which made a bulge under the skin and caused him great difficulty in riding a horse.

Although our first and third patients may never have this problem, they will be followed up, and should the inconvenience of the tail become intolerable, partial excision of the coccyx, as performed in our second patient, may be considered.

#### REFERENCES

- Bartels M.** Die geschwanzten Menschen. *Arch Antropol* 1883;**15**:45-131.
- Fára M, Smahel J.** Human tail. *Acta Chir Plast (Praha)* 1973;**15**:184-9.
- Gray's Anatomy*. 34th ed. London: Longmans, 1967:286-90.
- Lundberg GD, Parsons RW.** A case of a human tail. *Am J Dis Child* 1962;**104**:72-3.
- Miller CH.** Tailed humanity. *Med Surg Rep* 1881;**45**:165-6.
- Parsons RW.** Human tails. *Plast Reconstr Surg* 1960;**25**:618-21.
- Reiter A.** Die Frühentwicklung der menschlichen Wirbelsäule. *Z Anat Entwickl* 1944;**113**:203-27.
- Williams PL, Wendell-Smith CP, Treadgold S.** *Basic human embryology*. London: Pitman Medical Publishing Company, 1966:53,82-3.