

# HIP PAIN DURING ADOLESCENCE AFTER PERTHES' DISEASE

GARRY D. GROSSBARD

*From the Royal National Orthopaedic Hospital, London*

**Twelve patients with healed Perthes' disease who developed pain after a symptom-free period were studied. Several specific causes for the pain were found. These were osteochondritis dissecans with and without loose bodies, the hinging hip, the torn acetabular labrum, and meralgia paraesthetica. Case studies are presented as illustrations. The importance of arthrography in differentiating between these conditions is discussed.**

The number of adolescents presenting with pain in the hip after Perthes' disease in childhood is small (Ratliff 1956). However, there are a number of reports of such patients being subjected to procedures aimed at providing cover for the femoral head. Such procedures include pelvic osteotomies (Chiari 1980) and shelf arthroplasties (van der Heyden and van Tongerlo 1981). This implies that pain was a result of subluxation or extrusion of the femoral head from the acetabulum.

## MATERIAL AND METHODS

Twelve of the 95 patients with Perthes' disease admitted to the Royal National Orthopaedic Hospital under the care of Mr A. Catterall between 1971 and 1980 were over 10 years of age and at the stage in which their Perthes' disease was considered to be healed or healing. This represented 12.6 per cent of the cases.

These 12 patients were examined clinically and with plain radiography and arthrography. This allowed them to be separated into five groups: osteochondritis dissecans, without loose body (two patients), with loose body (two); hinging hip (four); tear of the acetabular labrum (one); meralgia paraesthetica (one); and no diagnosis (two).

## RESULTS

### **Osteochondritis dissecans (four patients).**

**Case 1.** A 14-year-old boy was diagnosed as having Perthes' disease on the right side three years before presentation. He complained of recurrent episodes of severe pain over a period of one year. There was no history of locking or catching of his hip. Radiographic examination revealed healed Perthes' disease with two osteochondral fragments. The arthrogram indicated that these fragments were not loose (Figs 1 and 2). Conservative treatment was undertaken.

**Case 2.** Another boy aged 15 years was admitted six years after the diagnosis of Perthes' disease was made. He had a two-year history of intermittent short episodes of severe pain. There were no symptoms between these painful episodes. The radiographs revealed only healed Perthes' disease but arthrography demonstrated a loose body within the hip (Figs 3 and 4). This was successfully removed at operation. The patient remains asymptomatic 10 months later.

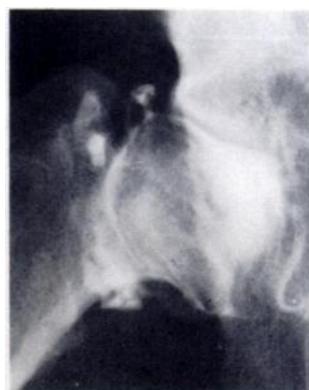

Fig. 1

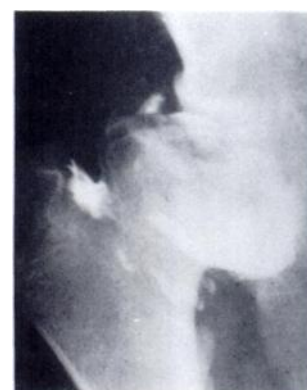

Fig. 2

Arthrograms of Case 1 showing two osteochondritic fragments firmly attached to the underlying femoral head. The head is relatively congruous with the acetabulum.

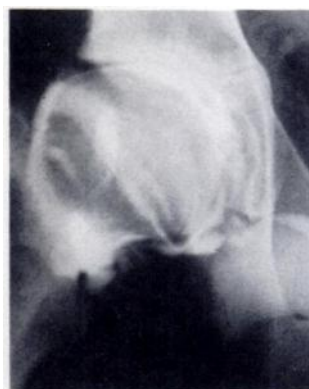

Fig. 3

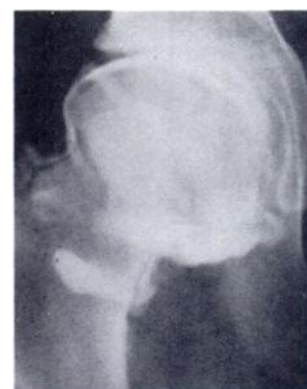

Fig. 4

Arthrograms of Case 2 showing a loose osteochondritic fragment completely surrounded by contrast material. The fragment alters its position with respect to the femoral head in different position of abduction and adduction.

This uncommon complication is well described in the literature with an incidence ranging from two to four per cent (Stillman 1966; Ratliff 1967; Kamhi and MacEwen 1975). It occurs at a stage after the lesion in

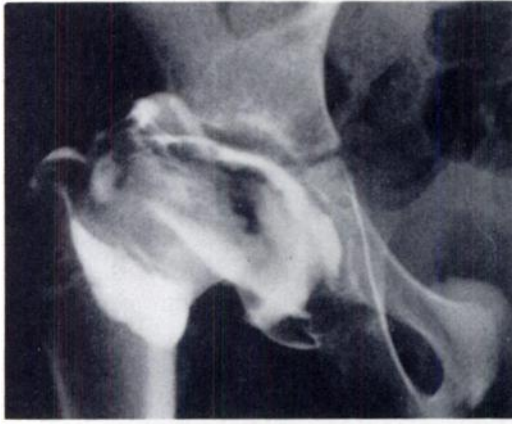

Fig. 5

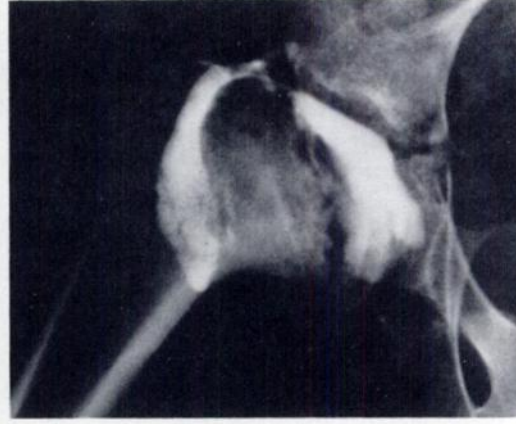


Fig. 6

Arthrogram of Case 3 in neutral (Fig. 5) and in abduction (Fig. 6) illustrating the increased medial pooling suggesting that the hip was hinging at the superior acetabular margin.

the femoral head appears to have healed, but there is a variable symptom-free period before it becomes clinically manifest. The incidence is highest in males in whom the age of onset of Perthes' disease has been greater than average (Kamhi and MacEwen 1975). The clinical features are generally intermittent pain and episodes of stiffness. The pain may have a distinct mechanical nature causing catching or locking of the hip, especially if the osteochondritic fragment is loose.

#### Hinging hip (four patients).

**Case 3.** A 12-year-old boy with Group 3 Perthes' disease diagnosed three years previously was admitted with recent onset of pain on walking only a short distance. On examination he had five degrees of fixed adduction deformity with only 20 degrees of adduction in fixed lateral rotation. Arthrography demonstrated a large flattened head with marked hinging on attempted abduction. The head was best seated in 20 degrees of adduction (Figs 5 and 6). He is now free from pain two and a half years after a 25 degree abduction osteotomy.

This condition has only recently been recognised. With overgrowth of the anterolateral aspect of the articular cartilage and crushing of the trabeculae in the bony epiphysis, the unossified portion of the femoral head tends to bulge out from under the lateral portion of the acetabular roof. As a result the leg is adducted and attempted abduction produces impingement of the femoral head against the superior acetabular rim which causes the hip to hinge at this point of contact. The resulting pain may occasionally be associated with a feeling of the hip "clunking" as it hinges in and out of the acetabulum. This situation is particularly troublesome when there is an adduction deformity of the hip. The symptoms are then produced on attempting to bring the leg into a neutral position (Catterall 1981).

#### Torn acetabular labrum (one patient).

**Case 4.** A 10-year-old boy presented with a two-year history of locking and a clinking sensation within his left hip. This occurred some six years after the diagnosis of Perthes' disease had been made. The radiograph was unhelpful, but arthrography revealed a tear of the superior part of his acetabular labrum (Fig. 7). This tear was isolated at operation and the tattered loose part excised. Six months after

operation he still had a minimal clicking sensation but no locking or pain.

This condition has not been previously described in the literature. A tear in the labrum may result from an alteration of the hip mechanics and the shape of the

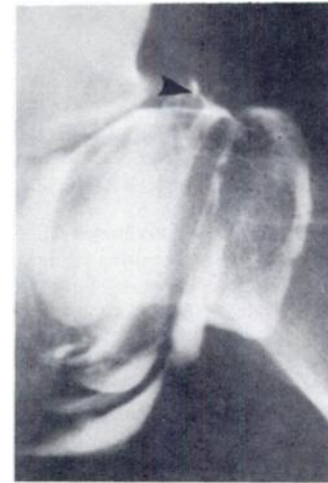

Fig. 7

Arthrogram of Case 4 showing the break in the smooth outline of the acetabular labrum (arrow). This tear was confirmed at operation.

femoral head. After a period free from symptoms the development of mechanical pain with locking of the hip may be suggestive of this condition.

#### Meralgia paraesthetica (one patient).

**Case 5.** A 14-year-old boy with Perthes' disease of the right hip had been treated by innominate osteotomy at the age of seven. He complained of pain in the groin and thigh for six months; this pain was made worse on movement of the hip but it was difficult to be certain whether this arose from the hip or not. The arthrogram was normal and exploration of the lateral cutaneous nerve of the thigh revealed a neuroma overlying the bony prominence at the site of the previous osteotomy. Excision of this portion of the lateral cutaneous nerve of the thigh cured his symptoms.

This condition is seen as a complication of a

previous operation for Perthes' disease. The lateral cutaneous nerve of the thigh is either stretched over a protruberance of bone at the site of a previous pelvic osteotomy or else it is involved in scar tissue within the surgical incision (Weikel and Habal 1977; Glasgow, Graham-Smith and Catterall 1978).

### DISCUSSION

Although pain in adolescents with Perthes' disease is uncommon, it is clear that there are several quite distinct causes for presentation. The differentiation of these conditions on purely clinical grounds is often difficult because of their overlapping symptoms. The use of arthrography under general anaesthesia has been invaluable as an aid not only in the differentiation of these conditions but also in planning appropriate management.

In osteochondritis dissecans arthrography is the only method that will determine whether or not the

osteochondritic fragment is loose within the hip (Goldman *et al.* 1976; Freiburger and Kaye 1979). In our illustrative Case 2 the loose body was only seen retrospectively after the arthrogram; it was not seen on the plain radiograph. This is an observation which has already been noted in previous reports (Stillman 1966; Goldman *et al.* 1976). The use of arthrography has also been of benefit in understanding the mechanism of hip pain, particularly in those patients with a hinging hip, and allows us to plan the appropriate osteotomy with relative accuracy.

In conclusion it is clear that careful examination of the adolescents with hip pain after Perthes' disease with the use of arthrography indicates conditions in which any procedure to produce better cover of the femoral head would be inappropriate. We wish to stress that the presence of these specific pathologies must be searched for and that, in our experience, simple uncovering of the lateral aspect of the femoral head was not a cause of symptoms.

I wish to thank Mr A. Catterall for his advice and for allowing me to study his patients at the Royal National Orthopaedic Hospital, London.

### REFERENCES

- Catterall A. Perthes' disease: a review. *Clin Orthop* 1981; (in press).
- Chiari K. *International symposium on children's hip problems*. Wilmington, Delaware. 1980.
- Freiburger RH, Kaye JJ. *Arthrography*. New York: Appleton-Century-Crofts, 1979:220.
- Glasgow M, Graham-Smith A, Catterall A. A cause of hip pain following the Smith-Petersen approach. Read at the Royal Society of Medicine, 1978.
- Goldman AB, Hallel T, Salvati EM, Freiburger RH. Osteochondritis dissecans complicating Legg-Perthes disease. *Radiology* 1976;121:561-6.
- Kamhi E, MacEwen GD. Osteochondritis dissecans in Legg-Calvé-Perthes disease. *J Bone Joint Surg [Am]* 1975;57-A:506-9.
- Ratliff AHC. Osteochondritis dissecans following Legg-Calvé-Perthes disease. *J Bone Joint Surg [Br]* 1967;49-B:108-11.
- Ratliff AHC. Pseudocoxalgia: a study of late results in the adult. *J Bone Joint Surg [Br]* 1956;38-B:498-512.
- Stillman BL. Osteochondritis dissecans and coxa plana: review of the literature with a personal case report. *J Bone Joint Surg [Br]* 1966;48-B:64-81.
- van der Heyden AM, van Tongerloo RS. Shelf operation in Perthes' disease. *J Bone Joint Surg [Br]* 1981;63-B:282.
- Weikel AM, Habal MB. *Meralgia paraesthetica*: a complication of iliac bone procurement. *Plast Reconstr Surg* 1977;60:572-4.