

THE INCIDENCE OF DEEP-VEIN THROMBOSIS AFTER UPPER TIBIAL OSTEOTOMY

A VENOGRAPHIC STUDY

R. S. TURNER, H. GRIFFITHS, F. W. HEATLEY

From St Thomas' Hospital, London, England

We performed postoperative venography on 84 consecutive patients who had undergone upper tibial osteotomy for medial compartment osteoarthritis of the knee. Deep-vein thrombosis was demonstrated in 41%. Only 15% of the cases were diagnosed clinically, all in the calf veins. Cases of proximal thromboses (3) and mixed-vein thromboses (12) were only revealed by venography.

J Bone Joint Surg [Br] 1993; 75-B:942-4.

Received 5 February 1993; Accepted 19 May 1993

Venography has revealed rates of deep-vein thrombosis (DVT) after total knee replacement of 56% (Stringer et al 1989), 72% (Lotke et al 1984) and 84% (Stulberg et al 1984), and a rate of 44.7% has been reported after tibial fractures (Hjelmstedt and Bergvall 1968). We describe the venographic findings in a consecutive series of patients who had Maquet (1984) barrel vault upper tibial osteotomies.

PATIENTS AND METHODS

Between January 1985 and September 1992, 81 patients who underwent their first upper tibial osteotomy for medial compartment osteoarthritis were entered into the study irrespective of previous surgery on the limb or previous history of thromboembolic disease. There were 27 women with a mean age of 54 years (30 to 69) and 54 men with a mean age of 55 (30 to 73).

Operative technique. The limb was exsanguinated with an Esmarch bandage and a pneumatic thigh tourniquet was applied. A graduated compression stocking was placed on the other limb. The fibular osteotomy was performed first, through a lateral approach along the

intermuscular septum posterior to the peroneal compartment; a small segment of bone was removed. Through a mid-line anterior incision the anterior tibial cortex was drilled using a sickle-shaped guide to define the shape of the dome. A smooth 3 mm diameter guide wire was used to drill the posterior cortex to prevent ensnaring of the soft tissues. Steinmann pins of 5 mm diameter were then drilled into the bone above and below the osteotomy site at the predetermined angle of correction. The anterior and posterior cortices were divided by joining the drill holes with an osteotome. The correction was achieved by manipulation of the fragments until the pins were parallel. The osteotomy was temporarily fixed with external clamps, and secured by five Blount staples. The Steinmann pins were removed and the tourniquet was deflated before wound closure. Suction drains were inserted into the fibular and tibial osteotomy sites and the leg was wrapped in thick wool and crepe bandages. The tourniquet time was usually 75 minutes and operating time 90 minutes.

Heparin (5000 IU) was given subcutaneously twice daily from 48 hours after the operation (after removal of the drains). Due to oversight, nine patients did not receive heparin. The patients started to walk after seven days, using splints and partial weight-bearing. Between seven and ten days postoperatively all 81 patients underwent ascending venography, on both sides in 42.

Venographically-demonstrated thrombosis was treated by immediate heparin followed by warfarin for three months. The incidence of thrombosis was analysed in relation to age, sex, weight and prophylactic use of heparin using logistic regression analysis.

RESULTS

Thrombosis occurred in 33 patients (41%) and non-fatal pulmonary embolus in one. Two patients had a previous history of thromboembolic disease but only one developed DVT. The incidence of DVT by sex and site is given in Table I.

Thrombosis was diagnosed clinically in seven patients in two of whom it was not demonstrated venographically. In the other five venography demonstrated calf-vein thromboses. Popliteal or iliofemoral DVT occurred

R. S. Turner, FRCS, Senior Registrar
H. Griffiths, MB BS, House Surgeon
F. W. Heatley, FRCS, Reader and Honorary Consultant in Orthopaedics
Orthopaedic Academic Unit, The Rayne Institute, St Thomas' Hospital,
Lambeth Palace Road, London SE1 7EH, UK.

Correspondence should be sent to Mr F. W. Heatley.

©1993 British Editorial Society of Bone and Joint Surgery
0301-620X/93/6677 \$2.00

in 15 patients, of whom 12 also had calf-vein thromboses. In none of these had proximal DVT been detected clinically.

Table I. Distribution of deep-vein thrombosis (DVT) by sex and site

Sex	Patients Number	DVT		Site		
		Number	Percentage	Calf	Popliteal	Iliofemoral
Male	53	24	45	21	3	6
Female	28	9	32	9	3	3
Total	81	33	41	30	6	9

In the 42 patients who had bilateral venography there was calf-vein thrombosis in the non-operated leg in only two. Although there was a greater proportion of DVT in men (45%) than in women (32%) the difference was not statistically significant ($\chi^2 = 1.31$, $p > 0.2$).

The incidence of DVT increased with age ($p < 0.05$; Fig. 1), but the increase with weight was not significant ($p > 0.1$).

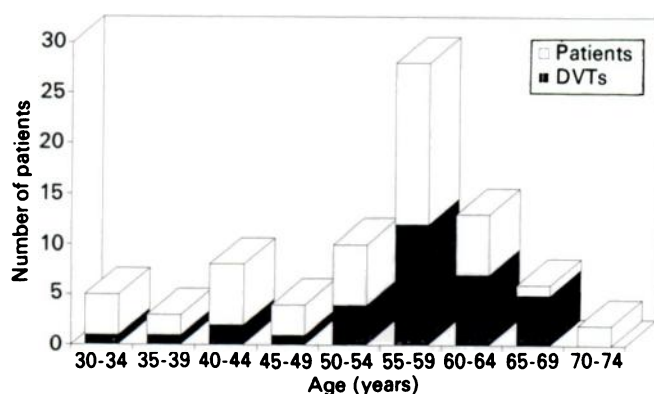


Fig. 1

Distribution of patients and deep-vein thrombosis by age.

No fatal pulmonary emboli occurred. Pulmonary embolus was diagnosed clinically in two patients but was confirmed by ventilation perfusion scan in only one. Both patients had venographically confirmed iliofemoral thrombosis.

Four of the nine patients who received no heparin prophylaxis developed DVT, an incidence which is not statistically different from that of the main group ($p > 0.5$).

DISCUSSION

We report an incidence of DVT of 41% after upper tibial osteotomy in a consecutive group of patients, most of whom received heparin from 48 hours after surgery. Very few papers on upper tibial osteotomy refer to the thrombotic complications. In a review of the English

literature (Heatley et al 1989), 19 cases of pulmonary embolism, five of them fatal, were found among 1647 upper tibial osteotomies, an incidence of emboli of 1.2% and a mortality of 0.3%. There were three other deaths recorded, two from myocardial infarction and one anaesthetic death. Only 46 cases of deep-vein thrombosis were reported, however, an incidence of 2.8% which is very low in relation to the number of emboli. Most of these thromboses were diagnosed purely on clinical grounds, only five being proven venographically. Recently, Matthews et al (1988) reported an incidence of clinical thrombosis of 6% but Coventry (1987), Cass and Bryan (1988) and Morrey (1989) did not refer to the complication. If DVT had been diagnosed by clinical signs in our series, we would have reported an incidence of 6%. Clinical diagnosis gave two false-positive results and a detection rate of only five in 33 (15%). Furthermore, none of the proximal high-risk thromboses was diagnosed clinically.

Twenty of the 47 thrombi in our series were restricted to the deep veins of the calf. Their significance remains a matter for debate (Philbrick and Becker 1988). Symptomatic pulmonary emboli have been reported to occur in up to 1.7% of patients with DVT in the calf (Hass et al 1992), recurrence in up to 29% (Lagerstedt et al 1985), post-thrombotic syndrome in up to 20% (Browse, Clemenson and Lea Thomas 1980) and propagation into proximal veins in 4% (Maynard, Sculco and Ghelman 1991).

We delayed the prophylactic administration of heparin until 48 hours after operation because of the risk that bleeding would lead to a compression syndrome in the calf. Whatever the rationale for this regimen, it must be concluded that it was ineffective in reducing the incidence of DVT to an acceptable level. It probably failed to influence the natural incidence, as the DVT rate was not significantly different in the small group in which heparin was inadvertently omitted.

No benefits in any form have been received or will be received from a commercial party related directly or indirectly to the subject of this article.

REFERENCES

- Browse NL, Clemenson G, Lea Thomas M. Is the postphlebotic leg always postphlebotic? Relation between phlebographic appearances of deep-vein thrombosis and late sequelae. *Br Med J* 1980; 281:1167-70.
- Cass JR, Bryan RS. High tibial osteotomy. *Clin Orthop* 1988; 230: 196-9.
- Coventry MB. Proximal tibial varus osteotomy for osteoarthritis of the lateral compartment of the knee. *J Bone Joint Surg [Am]* 1987; 69-A:32-8.
- Hass SB, Tribus CB, Insall JN, Becker MW, Windsor RE. The significance of calf thrombi after total knee arthroplasty. *J Bone Joint Surg [Br]* 1992; 74-B:799-802.
- Heatley FW, Lea Thomas ML, Giddins GEB, Hong A. Deep vein thrombosis in barrel vault tibial osteotomy: a pilot study. *J Bone Joint Surg [Br]* 1989; 71-B:729.
- Hjelmstedt Å, Bergvall U. Incidence of thrombosis in patients with tibial fractures: a phlebographic study. *Acta Chir Scand* 1968; 134:209-18.

- Lagerstedt CI, Olsson CG, Fagher BO, Oqvist BW, Albrechtsson U.** Need for long term anticoagulant treatment in symptomatic calf-vein thrombosis. *Lancet* 1985; 2:515-8.
- Lotke PA, Ecker ML, Alavi A, Berkowitz H.** Indications for the treatment of deep venous thrombosis following total knee replacement. *J Bone Joint Surg [Am]* 1984; 66-A:202-8.
- Maquet PGJ.** *Biomechanics of the knee: with application to the pathogenesis and the surgical treatment of osteoarthritis.* Second ed. Berlin, etc: Springer-Verlag, 1984.
- Mathiesen EB, Lindgren JU, Blomgren GGA, Reinhold FP.** Corrosion of modular hip prostheses. *J Bone Joint Surg [Br]* 1991; 73-B:569-75.
- Matthews LS, Goldstein SA, Malvitz TA, Katz BP, Kaufer H.** Proximal tibial osteotomy: factors that influence the duration of satisfactory function. *Clin Orthop* 1988; 229:193-200.
- Maynard MJ, Sculco TP, Ghelman B.** Progression and regression of deep vein thrombosis after total knee arthroplasty. *Clin Orthop* 1991; 273:125-30.
- Morrey BF.** Upper tibial osteotomy for secondary osteoarthritis of the knee. *J Bone Joint Surg [Br]* 1989; 71-B:554-9.
- Philbrick JT, Becker DM.** Calf deep venous thrombosis: a wolf in sheep's clothing? *Arch Intern Med* 1988; 148:2131-8.
- Stringer MD, Steadman CA, Hedges AR, et al.** Deep vein thrombosis after elective knee surgery: an incidence study in 312 patients. *J Bone Joint Surg [Br]* 1989; 71-B:492-7.
- Stulberg BN, Insall JN, Williams GW, Ghelman B.** Deep-vein thrombosis following total knee replacement: an analysis of six hundred and thirty-eight arthroplasties. *J Bone Joint Surg [Am]* 1984; 66-A:194-201.