SENSORY AND SYMPATHETIC INNERVATION OF THE VERTEBRAL ENDPLATE IN PATIENTS WITH DEGENERATIVE DISC DISEASE

M. F. BROWN, M. V. J. HUKKANEN, I. D. McCARTHY, D. R. M. REDFERN, J. J. BATTEN, H. V. CROCK, S. P. F. HUGHES, J. M. POLAK

From the Royal Postgraduate Medical School, Hammersmith Hospital, London, England

We obtained intervertebral discs with cartilage endplates and underlying cancellous bone at operation from patients with degenerative disc disease and then used immunohistochemical techniques to localise the nerves and nerve endings in the specimens. We used antibodies for the ubiquitous neuronal protein gene product 9.5 (PGP 9.5). Immunoreactivity to neuropeptide Y was used to identify autonomic nerves and calcitonin gene-related peptide (CGRP) and substance P to identify sensory nerves. Blood vessels were identified by immunoreactivity with platelet-endothelial cell-adhesion molecule (CD31; PECAM).

In a control group with no known history of chronic back pain, nerve fibres immunoreactive to PGP 9.5 and neuropeptide Y were most closely related to blood vessels, with occasional substance P and CGRP immunoreactivity. In patients with severe back pain and markedly reduced disc height, proliferation of blood vessels and accompanying nerve fibres was observed in the endplate region and underlying vertebral bodies. Many of these nerves were immunoreactive to substance P or CGRP, and in addition, substance P- and CGRP-immunoreactive nociceptors were seen unrelated to blood vessels. Quantification by image analysis showed a marked increase in CGRP-containing sensory nerve fibres compared with normal control subjects.

We speculate that a chemotactic response to products of disc breakdown is responsible for the proliferation of vascularity and CGRP-containing sensory nerves found in the endplate region and vertebral body adjacent to degenerate discs. The neuropeptides substance P and CGRP have potent vasodilatory as well as pain-transmitting effects. The increase in sensory nerve endings suggests increase in blood flow, perhaps as an attempt to augment the nutrition of the degenerate disc. The increase in the density of sensory nerves, and the presence of endplate cartilage defects, strongly suggest that the endplates and vertebral bodies are sources of pain; this may explain the severe pain on movement experienced by some patients with degenerative disc disease.

J Bone Joint Surg [Br] 1997;79-B:147-53.
Received 9 April 1996; Accepted after revision 16 August 1996

Intervertebral disc degeneration is common, affecting a considerable proportion of the population. The aetiology is largely unknown but it is thought that disc nutrition is involved.[1] There is radiological narrowing of the affected disc space with sclerosis of the endplates of the adjacent vertebral bodies. Both back pain and referred pain are common, accounting for more cases of sciatica than herniated nucleus pulposus.[2] When back pain predominates, the axial structures of the spine, such as the vertebral body, the disc, and the related ligaments, are often the sources of pain.

Several studies have described the sparse innervation of the peripheral annulus fibrosus,[3-7] and it is now agreed that the disc itself, comprising the inner annulus and nucleus, is without innervation even when there has been extensive neovascularisation. This suggests that other sites in the spine may cause pain.

Punctate lesions of the vertebral endplates are common in patients with the resorptive form of intervertebral disc degeneration. MRI has shown that disc material may herniate into the vertebral body and that blood vessels and fibrotic bone marrow from the vertebral body may invade the disc.[2,8] A hypothetical mechanism for pain production has therefore been proposed. Trauma and inflammation may cause the synthesis of factors such as bradykinin and prostanoids. These factors are capable of sensitising silent nociceptors which are usually unresponsive to even max-

M. F. Brown, PhD, FRCS Ed Orth, Senior Registrar
I. D. McCarthy, PhD, Senior Lecturer
D. R. M. Redfern, FRCS, Specialist Registrar
J. J. Batten, BSc, Technician
H. V. Crock, MS FRCS, Senior Lecturer
S. P. F. Hughes, MS FRCS Orth, Professor
Department of Orthopaedic Surgery
M. V. J. Hukkanen, PhD, Lecturer
J. M. Polak, MD, FRCPath, Professor
Department of Histochemistry
Royal Postgraduate Medical School, Hammersmith Hospital, Du Cane Road, London W12 0NN, UK.

Correspondence should be sent to Professor S. P. F. Hughes.

©1997 British Editorial Society of Bone and Joint Surgery
0301-620X/97/16814 $2.00

imal mechanical stimulation.[9,10] The nociceptors could then respond to changes in intradiscal pressure on movement and cause back pain. Different types of pain have been described, including both constant dull pain and shooting pain on movement. This suggests that different nerve fibres may be involved such as unmyelinated C-type fibres and thinly myelinated Aδ-type fibres which are characterised by their content of substance P and calcitonin gene-related peptide (CGRP) or CGRP only, respectively.

The nutrition of the disc is essentially by passive diffusion predominantly via vascular channels in the endplate regions, but convective flow may also contribute significantly.[1] We previously demonstrated, using microspheres, that the blood flow to the endplate in experimental models is similar to that in cortical bone.[11] Systemic administration of the neurotransmitters noradrenaline and acetylcholine has been shown to influence the blood flow in the vertebral endplate.[12] It would therefore appear that circulation in the endplate region is controlled by locally released neurotransmitters; this suggests the presence of neural elements within the vertebral body.

An array of neurotransmitters other than noradrenaline and acetylcholine has recently been discovered and they are proposed to play a role as vasoactive and nociceptive agents. We therefore investigated the presence of various types of potentially vasomotor and nociceptive nerve fibres with their differing neuropeptide content within the human vertebral body and endplate,.

PATIENTS AND METHODS

We investigated 15 patients of mean age 36 years (17 to 62; Table I) undergoing anterior lumbar discectomy and fusion for degeneration of the disc at one or two spinal levels from L1/L2 to L5/S1; most had severe back pain with or without sciatica. A total of 18 levels was fused and tissue obtained from each.

Similar samples were obtained from seven post-mortem control subjects with no record of chronic low back pain. Histopathology showed no significant endplate defects or other abnormalities in these intervertebral discs or cartilage endplates. Their mean age was 61 years (53 to 69).

Radiography and estimation of loss of disc height. We assessed loss of intervertebral disc height by measuring the ratio between disc height and width, using the method described by Ylikoski and Tallroth.[13] Comparative control measurements for each intervertebral level were made from a consecutive series of 40 routine lateral lumbosacral radiographs which had been reported as normal. The mean disc height to width ratios are listed in Table I.

Tissue preparation. Cores of disc and adjacent vertebral bodies were obtained using dowel cutting instruments.[2] The samples, cylinders of bone-disc-bone, were fixed in Zamboni's solution for 24 hours at 4°C with one change of the fixative. The tissues were then thoroughly washed with phosphate-buffered saline (PBS) containing 15% sucrose and 0.01% sodium azide, and decalcified in EDTA/PVP solution for four weeks according to the method of Hukkanen et al.[14] They were then thoroughly washed in the above buffer and cryostat blocks were prepared for tissue sectioning.

Table I. Details of radiological estimates of disc height of 15 patients with disc degeneration

Patient	Age (yr)	Sex	Level	H/W ratio	Mean	% of mean
1	45	F	L5/S1	ND*	ND	ND
2	43	F	L4/L5	0.105	0.268	*39*
			L5/S1	0.070	0.249	*28*
3	62	M	L3/L4	ND	ND	ND
4	21	M	L4/L5	0.105	0.268	*39*
			L5/S1	0.105	0.249	*42*
5	43	F	L4/L5	0.00	0.268	*0*
6	50	F	L4/L5	0.086	0.268	*32*
7	28	M	L3/L4	0.070	0.249	*28*
8	37	F	L5/S1	0.213	0.249	*86*
9	37	M	L5/S1	0.176	0.249	*71*
10	27	F	L5/S1	0.213	0.249	*86*
11	49	F	L1/L2	0.141	0.231	*61*
12	22	F	L4/L5	0.086	0.268	*32*
			L5/S1	0.070	0.249	*28*
13	17	F	L5/S1	0.070	0.249	*28*
14	25	F	L5/S1	ND	ND	ND
15	27	F	L5/S1	0.153	0.249	*61*

* not done (radiograph not available)

Immunocytochemistry and antisera. Frozen sections (15 μm) were immunostained according to the avidin-biotin-peroxidase method (Vector Laboratories, Peterborough, UK) with amplification of the end-product by a glucose oxidase-DAB-nickel method.[14] Table II gives the characteristics of protein gene product (PGP 9.5), CGRP, substance P, neuropeptide Y (NPY) and platelet-endothelial cell-adhesion molecule (PECAM) CD31 antisera. These have been described in detail elsewhere. Human spinal cord was used as a positive control to monitor the density of immunoreactivity and non-immune rabbit serum was used as a negative control. Antibodies for CGRP, substance P and NPY were further characterised for their specificity by incubation with their corresponding synthetic antigen (Table II). Histopathological assessment used haematoxylin/eosin and toluidine blue histochemistry.

Quantification and statistical analysis. We used a low-light charge-screen coupled CCTV camera (HV-720K, Hitachi, Denshi Ltd, Japan) interfaced with a Kontron VIDAS image-processing system to assess the total immunoreactive area in the sections immunostained for PGP 9.5 and CGRP. Nerves which were immunoreactive for substance P were too sparse for reliable quantification. The digital image consisted of a 512 × 512 matrix of pixels with 0 to 256 grey levels at a point. Immunoreactive nerve fibres were counted

Table II. Characteristics of antisera used in the study

Antigen	Nature/ localisation	Dilution	Absorption*	Source	Reference
PGP 9.5	Ubiquitous neuronal protein	1/6000	N/A†	Ultraclone, Cambridge, UK	Doran et al[31]
CGRP‡	Sensory neuropeptide	1/4000	0.1 nM/ml	Royal Postgraduate Medical School	Merighi et al[32]
Substance P§	Sensory neuropeptide	1/4000	1.0 nM/ml	RPMS	Merighi et al[32]
NPY	Sympathetic neuropeptide	1/4000	1.0 nM/ml	RPMS	Allen et al[33]
CD31¶	Endothelial cells	1/100	N/A	Dr AV Mazurov, Cardiology Research Centre, Moscow, Russia	Newman et al[34]

* antiserum absorbed with corresponding synthetic peptide; lowest concentration in which a significant reduction in immunoreactivity was noted
† not applicable
‡ synthetic rat α-CGRP peptide, antiserum cross-reacts with β-CGRP
§ synthetic rate peptide, antiserum may cross-react with other tchykinins;
¶ cluster of differentiation

using a ×10 objective magnification. Four non-serial sections were studied in each case giving a total of approximately 30 fields per section. The results of image-analysis quantification were expressed as the mean percentage area of PGP 9.5 or CGRP immunoreactivity of the total fields measured, and all the data are expressed as means ± SEM. Numerical differences between the cases studied were compared using the Mann-Whitney test (non-parametric, two-tailed); a value of $p < 0.05$ was taken as showing a significant difference between the two groups examined.

RESULTS

Measurement of disc height. Most patients showed a marked loss of intervertebral disc height. The mean reduction was 44.07 ± 6.2% (0 to 86%) according to the height-to-width (H/W) ratio measurements, compared with the lumbosacral radiographs reported as normal (Table I).

Innervation of vertebral bodies and cartilage endplates. Medullary cavities of vertebral bodies were shown to be innervated by both autonomic (PGP 9.5 and NPY) and sensory nerve fibres (PGP 9.5, substance P and CGRP) in both the patients and the control group. Perivascular nerve-fibre plexuses, immunoreactive to both PGP 9.5 and NPY, and to a much less degree to substance P and/or CGRP, were seen to enter vertebral bodies through nutrient foramina along with the arteries supplying them. The nerve fibres followed the vasculature into the deeper parts of the vertebral bodies, and ramified towards the cartilage endplates. The density of perivascular PGP 9.5- and NPY-immunoreactive fibres was most marked around large arteries (Fig. 1) and decreased as the vessels divided into arterioles.

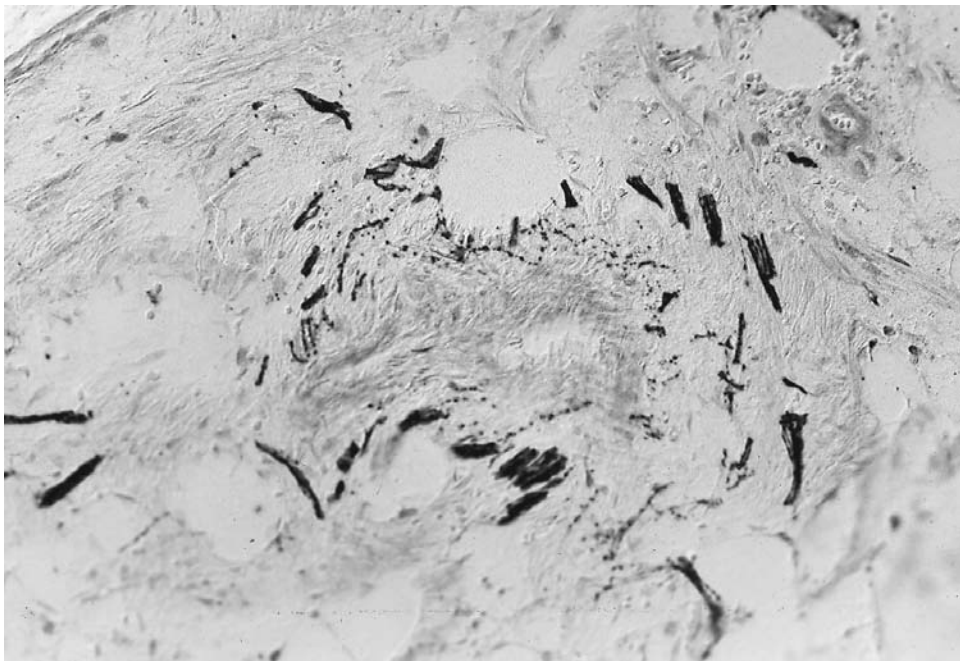

Fig. 1

Dense perivascular innervation is shown by antibodies to PGP 9.5 in a vertebral body near an endplate, taken from a patient with disc degeneration. Varicose fibres terminate locally and thicker bundles are targeted in more peripheral parts of the artery (× 210).

There were few substance P- and CGRP-immunoreactive fibres around these vessels. All neuronal epitopes, except NPY, were found in fibres terminating in the endplate region. These very fine nerve fibres were found in or near the endosteal surface of the calcified zone of the endplates, and were mostly free-ending. Several of the endplates studied, however, were found to contain small vascular spaces which occasionally also contained PGP 9.5-, substance P- and CGRP-immunoreactive nerve fibres associated with capillaries.

Many of the intervertebral discs and vertebral bodies were obtained from patients with advanced narrowing of the disc space. In these cases, histopathological findings included destruction of the disc material, erosion of the cartilage endplates, invasion of the bone-marrow space of the vertebral body by disc material, or vice versa, invasion of the intervertebral disc space by fibrotic bone-marrow material, and an increase in the vertebral body bone area (Fig. 2). Immunostaining for PECAM CD31 showed widespread proliferation of arterioles and capillaries which in some cases were seen to penetrate the intervertebral disc together with the fibrotic bone-marrow material (Fig. 3).

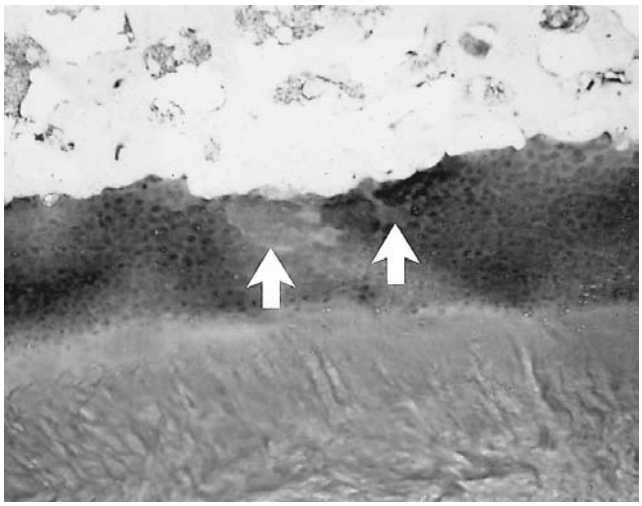

Fig. 2a

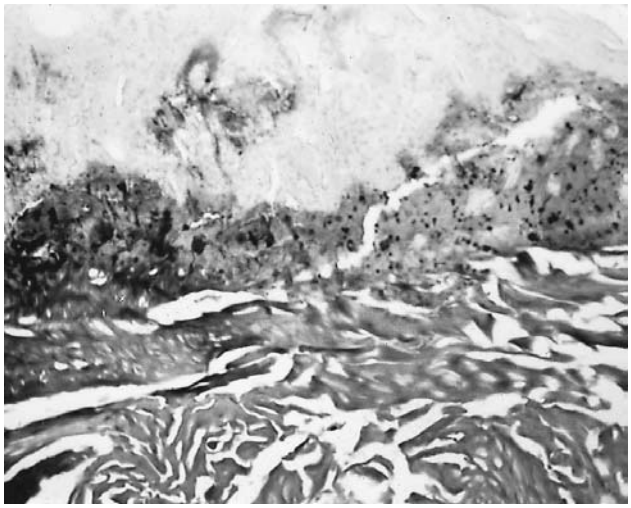

Fig. 2b

Figure 2a – Photomicrograph showing the morphology of an endplate interface taken from a patient with loss of disc height. No major histopathological changes were observed although in some areas the endplates were affected by minor erosions (arrows). Figure 2b – Photomicrograph showing morphology of a severely affected intervertebral disc and adjacent endplates taken from a patient with very advanced loss of disc height. The intervertebral disc is very disorganised and largely destroyed. The cartilage endplate is very severely eroded and partly calcified. Single chondrocytes can be easily recognised by their strong staining for Toluidine Blue. In these patients, punctate endplate defects were commonly seen (× 32).

Fig. 3a

Fig. 3b

Photomicrograph showing the proliferation of arterioles and capillaries in the vertebral body (a) and vertebral body/endplate interface (b) taken from a patient with severe disc degeneration (PECAM × 80).

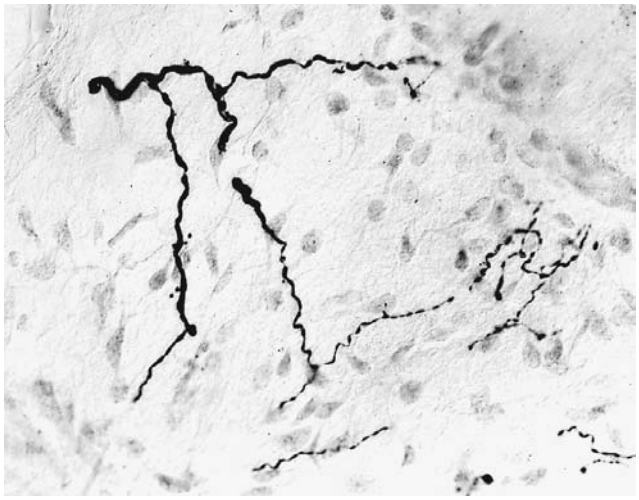

Fig. 4a

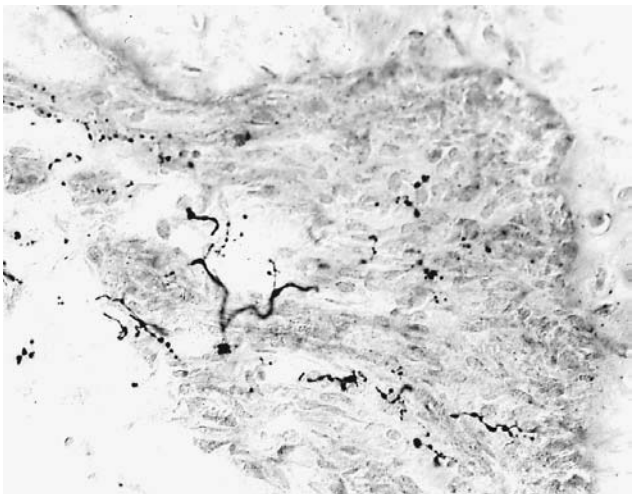

Fig. 4b

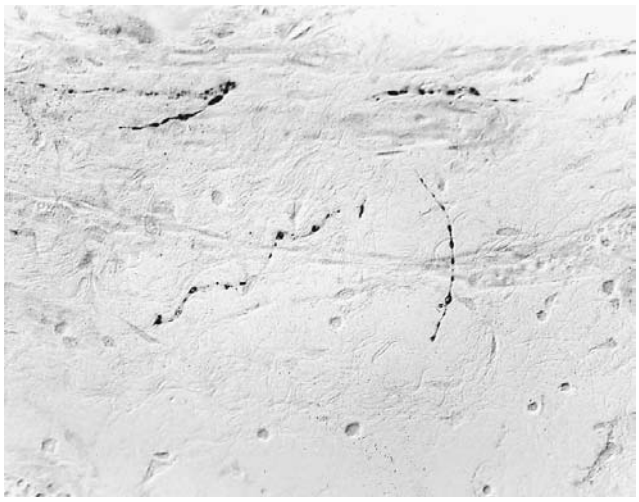

Fig. 4c

Fig. 4d

Photomicrographs showing PGP-9.5-immunoreactive free-ending nociceptors in medullary space of a vertebral body near the endplate (a) and PGP 9.5-immunoreactive nociceptors terminating into the calcified zone of the endplate in a specimen taken from a patient with severe disc degeneration (b). In these cases the bone marrow was often fibrotic near the endplate cartilage defects and in such areas proliferation of free-ending nerve fibres was apparent. Substance P- (c) and CGRP-immunoreactive (d) nerve fibres of very fine calibre were found near the endplate cartilage defects and the presence of neuropeptides substance P and CGRP in these fibres is evidence of their natures as nociceptors (× 320).

Immunostaining for PGP 9.5 showed proliferation of varicose nerve fibres of fine calibre unrelated to the vasculature; these therefore corresponded morphologically to typical free-ending nociceptors (Fig. 4a). Most of these nociceptors were perpendicular to the disc endplate and ramified as they reached endosteal surface of the endplate (Fig. 4b). These findings were further confirmed by immunostaining of serial sections using antibodies for substance P and CGRP (Figs. 4c and 4d). Localisation of PGP 9.5-, substance P- and CGRP-immunoreactive nerve fibres also demonstrated the presence and sprouting of free-ending nociceptors adjacent to the cartilage lesions of the endplate.

Innervation of intervertebral discs. Intervertebral discs themselves were found to contain PGP 9.5-, NPY-, CGRP- and substance P-immunoreactive fibres only in the peripheral parts of the annulus fibrosus. These nerve fibres were mostly perivascular. The central part of the annulus fibrosus and nucleus pulposus was devoid of any neuronal elements, although vascular proliferation into the disc space was evident in patients with severe reduction in disc height.

Image analysis quantification. The mean density of PGP 9.5-immunoreactive nerve fibres in the patient group was $4.0 \times 10^{-4} \pm 0.5 \times 10^{-4}\%$, compared with $4.7 \times 10^{-4} \pm 0.4 \times 10^{-4}\%$ in the control group ($p = 0.327$). The mean density of CGRP-immunoreactive nerve fibres in the patient group was $6.4 \times 10^{-5} \pm 2.0 \times 10^{-5}\%$, compared with $3.6 \times 10^{-8} \pm 1.7 \times 10^{-8}\%$ in the control group

($p = 0.0003$).

DISCUSSION

Our study of the innervation of the vertebral endplate has provided new findings on the vascularity of the endplates of degenerate intervertebral discs. We assume that the endplate microcirculation supplies most of the nutrition of at least the nucleus pulposus, and suggest that failure of nutrition, and death of the cells of the disc, is a mechanism of disc degeneration. Such degeneration tends to cause a mixture of back pain and symptoms of nerve-root compression, both neurogenic and radicular. A recent paper has shown a possible explanation for the distribution of pain in such cases.[15] Such symptoms can be treated by decompression alone, or by decompression with fusion, depending on the predominance of back pain. Our patients with this diagnosis were considered to require fusion because of the severity of their back pain. Anterior fusion as opposed to posterolateral intertransverse fusion was postulated to allow eradication of the pain source and give a more mechanically sound fusion.

Failure of nutrition may be reflected in the pattern of the blood vessels and perivascular nerves within the endplate region. We have shown that the vascular networks in vertebrae are innervated by vasomotor nerve fibres, suggesting neural control of disc nutrition. By comparing patterns of innervation in apparently normal post-mortem discs with those in severely degenerate diseased discs, we have shown an increase in the density of nerve fibres containing sensory neuropeptide CGRP in highly localised areas with greater degeneration. This finding suggests a mechanism for the neovascularisation of degenerate discs[2] and is analogous to the chemotactic response thought to be responsible for the development of cartilage canals in the embryology of bone.[16,17] Quantification of PGP 9.5 immunoreactive fibres did not show an increase in the mean value of nerve density in the patients, which could be explained by the very local sites of increased innervation observed in the sections. The mean density of CGRP immunoreactive fibres, however, was significantly increased.

PGP 9.5 fibres in particular appeared to be perivascular, whereas CGRP fibres were not related to the vasculature, and corresponded to C- and A-∂-type nociceptors in patients with degenerative disc disease. We consider that our observation of local increases in vascularity and innervation in our patients probably represent responses to disc degeneration. The demonstration of sympathetic perivascular innervation in both normal and pathological discs is consistent with the hypothesis that changes in blood flow could contribute to disc degeneration. In a recent cadaver study, angiographic and histological aspects of ingrowth of blood vessels in disc degeneration were examined[18] and it was suggested that vascular changes occurred before disc degeneration at all the spinal levels studied. Normal anastomosing arteries in the posterior ligament were obliterated with advancing degeneration, but the vascularity of the anterolateral annulus increased with degeneration. These observations agree with our findings.

The normal intervertebral disc is avascular[19] and receives its nutrition by diffusion from vessels in the endplate and around the annulus.[20,21] In man the relative contributions are unknown, but the importance of the endplate route has been stressed.[22] Using hydrogen-washout techniques in the canine lumbar spine Ogata and Whiteside[23] showed that the endplate route was predominant for nutrition of the disc. Crock et al[24] have studied the distribution of the vessels and shown capillaries ending in terminal dilatations at the bone-cartilage junction of the vertebral endplate.[19,24]

These findings have implications for the metabolism of the disc. Holm et al[25] have shown that the oxygen tension in the centre of the canine disc is extremely low, with a high lactate concentration. This was extrapolated to the human disc by Maroudas,[26] with the conclusion that the metabolism is largely anaerobic. There is also a clear relationship between the density of cells and distance from the periphery, both in the case of articular cartilage[27] and the disc.[28] The permeability of the endplate has also been investigated qualitatively by Nachemson[21] and quantitatively by Urban et al[29] who showed that, in contrast to articular cartilage, the cartilage endplate of the disc is permeable, especially towards the middle portion adjacent to the nucleus pulposus. This may be accounted for by the presence of cartilage canals in vertebral endplates, as shown by Whalen et al.[30] We suggest that nutritional factors limit the density of cells and hence the ability to maintain a normal turnover of matrix components. This leads to the conclusion that any reduction in nutrition or oxygen delivery must lead to a loss of matrix, loss of water because of the effect on swelling pressure, and loss of disc height.

We have used immunohistochemical techniques to demonstrate vascularity and, for the first time, individual modalities of innervation in the vertebral endplate and body, and have attempted to relate this to disc pathology. We suggest that disorders of nutrition, possibly caused by neural disturbances, may lead to disc degeneration, and present evidence that in the most degenerate discs at least, a process of neovascularisation may occur. Increase in the density of CGRP-containing sensory nerves, together with the presence of punctate cartilage endplate defects, strongly suggests that the endplates and vertebral bodies are sources of pain and may explain the extreme pain on movement experienced by some patients with degenerative disc disease.

We are grateful to Dr T. Shiraishi for assistance in collection of the samples. The work was funded by the Arthritis and Rheumatism Council, UK.

No benefits in any form have been received or will be received from a commercial party related directly or indirectly to the subject of this article.

REFERENCES

1. **Urban JP, Holm S, Maroudas A, Nachemson A.** Nutrition of the intervertebral disc: effect of fluid flow on solute transport. *Clin Orthop* 1982;170:296-302.
2. **Crock HV.** *A short practice of spinal surgery.* Wien: Springer-Verlag, 1993:1-44.
3. **Yoshizawa H, O'Brien JP, Thomas-Smith W, Trumper M.** The neuropathology of intervertebral discs removed for low-back pain. *J Pathol* 1980;132:95-104.
4. **Weinstein J, Claverie W, Gibson S.** The pain of discography. *Spine* 1988;13:1344-8.
5. **Konttinen YT, Grönblad M, Antti-Poika I.** Neuroimmunohistochemical analysis of peridiscal nociceptive neural elements. *Spine* 1990;15:383-6.
6. **Grönblad M, Weinstein JN, Santavirta S.** Immunohistochemical observations on spinal tissue innervation: a review of hypothetical mechanisms of back pain. *Acta Orthop Scand* 1991;6:614-22.
7. **Ashton IK, Roberts S, Jaffray DC, Polak JM, Eisenstein SM.** Neuropeptides in the human intervertebral disc. *J Orthop Res* 1994;12:186-92.
8. **Shiraishi T, Crock HV, Bydder G, Lewis P.** *Studies of punctate vertebral end plate defects in resorptive disc disease*. London: Society for Back Pain Research, 1993.
9. **Birrell GJ, McQueen DS, Iggo A, Grubb BD.** Prostanoid-induced potentiation of the excitatory and sensitizing effects of bradykinin on articular mechanonociceptors in the rat ankle joint. *Neuroscience* 1993;54:537-44.
10. **Cross SA.** Pathophysiology of pain. *Mayo Clin Proc* 1994;69: 375-83.
11. **Hughes SPF, Wallace AL, McCarthy ID, et al.** Measurement of blood flow to the vertebral bone and disc. *Eur Spine J* 1993;2:96-8.
12. **Wallace AL, Wyatt BC, McCarthy ID, Hughes SP.** Humoral regulation of blood flow in the vertebral endplate. *Spine* 1994;19:1324-8.
13. **Ylikoski M, Tallroth K.** Measurement variations in scoliotic angle, vertebral rotation, vertebral body height, and intervertebral disc space height. *J Spinal Disord* 1990;3:387-91.
14. **Hukkanen M, Konttinen YT, Santavirta S, et al.** Rapid proliferation of calcitonin gene-related peptide-immunoreactive nerves during healing of rat tibial fracture suggests neural involvement in bone growth and remodelling. *Neuroscience* 1993;54:969-79.
15. **Nakamura S-I, Takahashi K, Takahashi Y, Yamagata M, Monija H.** The afferent pathways of discogenic low-back pain: evaluation of L2 spinal nerve infiltration. *J Bone Joint Surg [Br]* 1996;78-B: 606-12.
16. **Hintzsche E.** Anatomische Gesellschaft Verhandlungen 1927-28. *Ztschr für Mikroscopisch-Anatomische Forshung* 1927;S:61-126.
17. **Hurrell DJ.** The vascularisation of cartilage. *J Anat* 1935;69:47-61.
18. **Kauppila LI.** Ingrowth of blood vessels in disc degeneration: angiographic and histological studies of cadaveric spines. *J Bone Joint Surg [Am]* 1995;77-A:26-31.
19. **Crock HV, Goldwasser M.** Anatomical studies of the circulation in the region of the vertebral end-plate in adult greyhound dogs. *Spine* 1984;9:702-6.
20. **Brodin H.** Paths of nutrition in articular cartilage and intervertebral discs. *Acta Orthop Scand* 1955;24:177-83.
21. **Nachemson A, Lewin T, Maroudas A, Freeman MAR.** In vitro diffusion of dye through the end-plates and the annulus fibrosus of human inter-vertebral discs. *Acta Orthop Scand* 1970;41:589-607.
22. **Bernick S, Cailliet R.** Vertebral end-plate changes with ageing of human vertebrae. *Spine* 1982;7:97-102.
23. **Ogata K, Whiteside LA.** Nutritional pathways of the intervertebral disc: an experimental study using hydrogen washout technique. *Spine* 1981;6:211-6.
24. **Crock HV, Goldwasser M, Yoshizawa H.** Vascular anatomy related to the intervertebral disc. In: Ghosh P, ed. *The biology of the intervertebral disc* Florida: CRC Press, 1988;1:109-33.
25. **Holm S, Maroudas A, Urban JP, Selstam G, Nachemson A.** Nutrition of the intervertebral disc: solute transport and metabolism. *Connect Tissue Res* 1981;8:101-19.
26. **Maroudas A.** Nutrition and metabolism of the intervertebral disc. In: White AA, ed. *Proceedings of the Workshop of Idiopathic Low Back Pain.* Fresno, California: P Mosley, 1982.
27. **Stockwell RA.** The interrelationship of cell density and cartilage thickness in mammalian articular cartilage. *J Anat* 1971;109:411-21.
28. **Maroudas A, Stockwell RA, Nachemson A, Urban J.** Factors involved in the nutrition of the human lumbar intervertebral disc: cellularity and diffusion of glucose in vitro. *J Anat* 1975;120:11-30.
29. **Urban JPG, Holm S, Maroudas A, Nachemson A.** Nutrition of the intertebral disk: an *in vivo* study of solute transport. *Clin Orthop* 1977;129:101-14.
30. **Whalen JL, Parke WW, Mazur JM, Stauffer ES.** The intrinsic vasculature of developing vertebral end plates and its nutritive significance to the intervertebral discs. *J Pediatr Orthop* 1985;5:403-10.
31. **Doran JF, Jackson P, Kynoch PA, Thompson RJ.** Isolation of PGP9.5: a new human neurone-specific protein detected by high resolution two-dimensional electrophoresis. *J Neurochem* 1983;40: 1542-7.
32. **Merighi A, Polak JM, Gibson SJ, et al.** Ultrastructural studies of calcitonin gene-related peptide tachykinins- and somatostatin-immunoreactive neurones in rat dorsal root ganglia: evidence for the colocalization of different peptides in single secretory granules. *Cell Tissue Res* 1988;254:101-9.
33. **Allen JM, Polak JM, Bloom SR.** Presence of the predicted C-flanking peptide of neuropeptide Y (CPON) in tissue extracts. *Neuropeptides* 1985;6:95-100.
34. **Newman PJ, Hillery CA, Albrecht R, et al.** Activation-dependent changes in human platelet PECAM-1: phosphorylation, cytoskeletal association, and surface membrane redistribution. *J Cell Biol* 1992; 119:239-46.