EARLY DETERIORATION AFTER MODIFIED ROTATIONAL ACETABULAR OSTEOTOMY FOR THE DYSPLASTIC HIP

M. MATSUI, K. MASUHARA, K. NAKATA, T. NISHII, N. SUGANO, T. OCHI

From Osaka University, Japan

We performed a modified, rotational acetabular osteotomy through a lateral transtrochanteric approach on 19 hips in 18 patients with a dysplastic joint. Six hips in six patients were operated on using the original approach. The mean age at operation was 28 years (14 to 54) and the mean period of follow-up 2.3 years (1 to 4.4).

Clinical evaluation using the Merle d'Aubigné score showed excellent or good results in 76%. Radiologically, 15 hips showed good acetabular remodelling and no signs of progressive osteoarthritis. In ten hips (40%) there was chondrolysis and collapse of the transferred acetabulum or both within one year, although this gave only mild pain in some patients. Factors which were significantly associated with the grade of outcome included age at the time of operation, the thickness of the transferred acetabulum, failure to use a bone graft, and a transtrochanteric approach.

J Bone Joint Surg [Br] 1997;79-B:220-4.
Received 27 August 1996; Accepted after revision 15 October 1996

Since 1978 we have used dome osteotomy of the pelvis to treat some skeletally-mature patients under 50 years of age for osteoarthritis secondary to hip dysplasia.[1] This operation creates a weight-bearing surface which is not totally congruent and requires subsequent remodelling of the head of the femur and acetabulum. Some patients who have a severely dysplastic hip or a secondary acetabulum cannot be treated successfully by dome osteotomy. We have therefore performed a modified rotational acetabular osteotomy (RAO) on these patients since 1991.

RAO[2-5] entails an *en-bloc* circumferential osteotomy around the acetabulum and rotation of the fragment to improve coverage of the head of the femur. Spherical acetabular osteotomy,[6] dial osteotomy[7] and some other periacetabular osteotomies[8,9] are also designed to achieve this, and good clinical and radiological results have been reported for these procedures.

We describe our short-term results after RAO in an attempt to identify the indications and risks of the method.

PATIENTS AND METHODS

Between July 1991 and October 1994, RAO was performed on 25 hips in 23 skeletally-mature patients with early osteoarthritis secondary to hip dysplasia. There were 22 women and one man with a mean age of 28 years (14 to 54). Radiographs taken before operation showed an improved congruity in abduction. Two patients had bilateral procedures. The operation was on the left side in 17 patients and on the right in eight and the main indication was the relief of pain. Fifteen hips had been treated previously for congenital dislocation and five had had previous operations, three open reductions, one derotation varus femoral osteotomy, and one tectoplasty. The patients were followed up for a mean 2.3 years (1 to 4.4) after RAO.

Operative technique. The technique has been described in detail,[4] but we made some modifications. In 19 hips we used a lateral transtrochanteric approach to expose the entire circumference of the acetabulum and preserve the strength of the hip abductors.[10] In 11 hips a slab of bone was taken from the femur where the greater trochanter was detached and used to fill the space between the ilium and the rotated acetabulum. In the first six hips we used a combination of the anterior iliofemoral and posterior approaches through a single anterior convex skin incision.[4] One or two cortical plate grafts and numerous cancellous bone chips from the external wall of the iliac wing were used to fill the gap between the ilium and the acetabulum. The acetabulum and the bone graft were stabilised by Kirschner wires passed into the bony pelvis. A cast was not used and active exercises were begun in the third week

M. Matsui, MD, PhD, Assistant Professor
K. Masuhara, MD, PhD, Associate Professor
K. Nakata, MD, Course Student
T. Nishii, MD, Course Student
N. Sugano, MD, PhD, Assistant Professor
T. Ochi, MD, PhD, Professor and Chairman
Department of Orthopaedic Surgery, Osaka University Medical School, 2-2 Yamada-oka, Suita 565, Japan.

Correspondence should be sent to Dr M. Matsui.

©1997 British Editorial Society of Bone and Joint Surgery
0301-620X/97/27202 $2.00

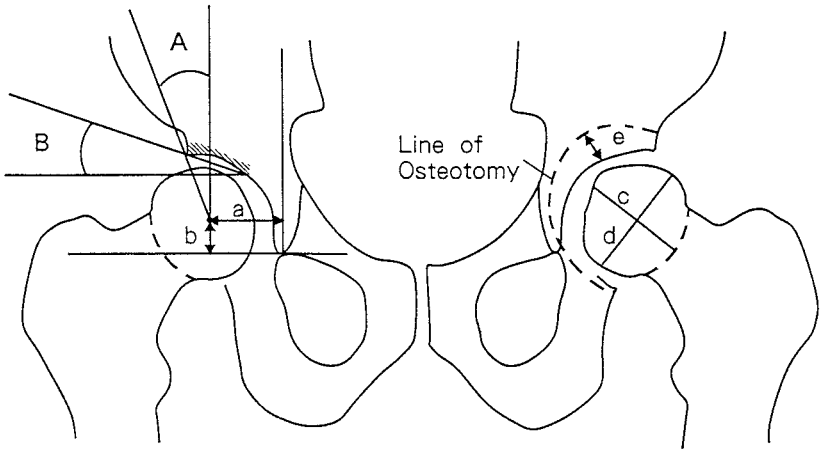

Fig. 1

Diagram showing the measurements, angles and ratios: A, Wiberg's CE angle; B, acetabular roof obliquity; a, horizontal distance; b, vertical distance; d/c > 1.1, deformed femoral head; d/c < 1.1, spherical femoral head; e, thickness of transferred acetabulum.

after operation. The wires were removed through a small skin incision in the sixth or seventh week after which partial weight-bearing on two crutches was allowed. The crutches were usually discarded four to five months after surgery.

The clinical results were evaluated using the Merle d'Aubigné and Postel hip score,[11] which assigns a maximum of six points for the three categories of pain, mobility, and gait function. A full score of 18 denotes normal hip function. Accordingly, 17 or 18 points were considered excellent, 15 or 16 points good, 13 or 14 points fair and 12 points or less poor.

Regular anteroposterior radiographs of the pelvis were taken. The centre-edge (CE) angle[12] and acetabular-roof obliquity[13] were used as indices of coverage. To evaluate the change in position of the femoral head after surgery we used distances a and b (Fig. 1). Deformity of the femoral head was evaluated by measuring the ratio of the major and minor axes in the anteroposterior view.[14] A value of 1.1 or less indicated a spherical head and of more than 1.1 a deformed head. The thickness of the transferred acetabulum was measured at the widest portion.

RESULTS

No patient had a nerve injury, thromboembolism, or an infection. In one patient, the osteotome entered the hip during the operation; a second, extra-articular osteotomy was then carried out with a good clinical and radiological result (Fig. 2).

Fig. 2a

Fig. 2b

Fig. 2c

A 26-year-old woman who presented with a painful right hip, scoring 12 points. Figure 2a – The preoperative radiograph shows acetabular dysplasia. Figure 2b – One week after a periacetabular osteotomy without trochanteric detachment in which the osteotome had penetrated the acetabular cartilage. Figure 2c – One year later there was excellent remodelling of the reconstructed acetabulum and the hip score was 18 points.

Excellent or good results were seen in 19 hips (76%), but chondrolysis of the hip and collapse of the transferred acetabulum occurred within a year in ten (40%) of the 25 hips (Figs 3 to 5). This, however, gave only mild pain in some. We compared the ten with a poor outcome with the 15 hips with a good outcome.

The mean age at operation was 25 years in the good group and 33 years in the poor group. The mean hip score improved from 14.8 to 16.8 points at final follow-up in the good group, mainly from relief of pain. Walking ability improved from 5.1 to 5.6 points. In the poor group the mean hip score deteriorated from 14.5 to 14.1 points. The CE angle improved from a mean of 0.3° to a mean of 34° in the good group and from –5.3° to 29.6° in the poor group. Obliquity of the acetabular roof improved from a mean of 22.3° to 0.3° in the good group and from 34.3° to 9.5° in the poor group. The acetabular coverage improved in both groups with no significant difference between them. Distance 'a' changed from a mean of 38.6 mm to 38 mm in the good group and from 39.5 mm to 36 mm in the poor group. Distance 'b' remained unchanged in both groups as did the position of the femoral head. In the good group, 11 heads were spherical and four deformed, while in the poor group nine were spherical and one deformed. The transtrochanteric approach had been used in 10 of 15 cases in the good group and in all of the poor group. The mean thickness of the transferred acetabulum was 13.2 mm in the good group and 10.3 mm in the poor group. Factors associated with a risk of failure were an age of 30 years or more at the time of operation, the transtrochanteric approach, failure to use an acetabular bone graft, and a transferred acetabulum less than 9 mm thick (Table I).

DISCUSSION

Our results have shown that early deterioration can occur after periacetabular osteotomy for early osteoarthritis secondary to hip dysplasia. The principal finding in these patients was joint-space narrowing on the radiographs, indicating chondrolysis. Necrosis or resorption of the acetabular fragment was often associated with chondrolysis.

Why did this complication occur? MRI of several hips showed a distinct change of signal intensity in the transferred acetabulum. Leitz and Reck[15] have stated that necrotic areas in the acetabular portion and osteoarthritic changes occurring a few years after triple osteotomy are explained by biomechanical causes. The very early occurrence of the changes after periacetabular osteotomy in our patients, however, rules out this explanation. The chondrolysis and necrosis may have resulted from trophic disturbances because of the thinness of the transferred acetabulum and the transtrochanteric approach, which may impair the circulation around the acetabulum and hip and particularly to the capsule. Wagner[6] considered that care should be taken to keep the osteotomy at least 10 mm from the acetabular roof to avoid trophic disturbance of the acetabulum and breakthrough into the acetabular cavity. Ninomiya[5] reported that necrosis of the acetabulum could occur when the osteotomy was too thin. A thick acetabular fragment is necessary to preserve the branches of the obturator vessels.

Fig. 3a

Fig. 3b

Fig. 3c

A 21-year-old woman with a dysplastic hip after congenital dislocation, and a hip score of 14 points. Figure 3a – The preoperative radiograph shows subluxation. Figure 3b – Two weeks after operation, there was good coverage by the transferred acetabulum. Figure 3c – Eighteen months later, there is proximal acetabular osteolysis associated with progressive chondrolysis. The hip score was 12 points.

Fig. 4a

Fig. 4b

Fig. 4c

Fig. 4d

A 34-year-old man with early osteoarthritis after congenital dislocation of the hip, and a score of 16 points. Figure 4a – The preoperative radiograph shows severe acetabular dysplasia. Figure 4b – Radiograph two weeks after periacetabular osteotomy. Figure 4c – Six months postoperatively, there is chondrolysis of the joint and nonunion of the transferred acetabulum. Figure 4d – Two years later there is proximal migration of the femoral head. The hip score was 14 points.

Fig. 5a

Fig. 5b

Fig. 5c

A 47-year-old woman with osteoarthritis of the left hip and a hip score of 15 points. Figure 5a – The preoperative radiograph shows early osteoarthritis. Figure 5b – A periacetabular osteotomy was performed through a transtrochanteric approach. Figure 5c – One year later there is marked narrowing of the joint space. The hip score remained at 15 points.

Table I. Relationship between radiological failure and risk factors

Factors	Good group (n = 15)	Poor group (n = 10)	p value*
Age in years			
14 to 30	13	4	
>30	2	6	0.014
Sphericity			
Spherical	11	9	
Deformed	4	1	0.31
Transtrochanteric approach			
Yes	10	10	
No	5	0	0.041
Graft			
Yes	12	3	
No	3	7	0.012
Thickness of transferred acetabulum (mm)			
≥10	15	4	
<9	0	6	0.0006

* chi-squared test

Ninomiya and Tagawa[4] described gradual narrowing of the joint space in the year after operation in two patients after penetration of the acetabular cartilage by an osteotome. In the only patient in our series in whom the osteotome penetrated the acetabular cartilage, the joint space did not show narrowing, perhaps because a thick acetabular fragment (17 mm) was obtained at the second osteotomy. Traumatic fracture of the acetabulum rarely causes acute chondrolysis; it is therefore likely that this complication results from cutting the acetabular portion too thinly.

Millis[16] stated that reconstructive surgery, including periacetabular osteotomy, is possible only if the articular cartilage retains enough biological plasticity to adjust to the reorientation imposed by the operation, and in our series the younger patients did better. The presence of a spherical or deformed head was not a significant factor, but may well influence the long-term outcome.

Periacetabular osteotomy is a risky operation because the development of early osteoarthritis may be accelerated by loss of joint cartilage. The procedure should be restricted to younger patients and it is essential to create a thick acetabular fragment.

No benefits in any form have been received or will be received from a commercial party related directly or indirectly to the subject of this article.

REFERENCES

1. **Anwar MM, Sugano N, Matsui M, Takaoka K, Ono K.** Dome osteotomy of the pelvis for osteoarthritis secondary to hip dysplasia: an over five-year follow-up study. *J Bone Joint Surg [Br]* 1993;75-B:222-7.
2. **Nakamura S, Ninomiya S, Takatori Y, et al.** Polylactide screws in acetabular osteotomy: 28 dysplastic hips followed for 1 year. *Acta Orthop Scand* 1993;64:301-2.
3. **Nakamura T, Yamaura M, Nakamitu S, Suzuki K.** The displacement of the femoral head by rotational acetabular osteotomy: a radiographic study of 97 subluxated hips. *Acta Orthop Scand* 1992;63:33-6.
4. **Ninomiya S, Tagawa H.** Rotational acetabular osteotomy for the dysplastic hip. *J Bone Joint Surg [Am]* 1984;66-A:430-6.
5. **Ninomiya S.** Rotational acetabular osteotomy for the severely dysplastic hip in the adolescent and adult. *Clin Orthop* 1989;247:127-37.
6. **Wagner H.** Osteotomies for congenital hip dislocation. In: *The Hip.* Procs of the 4th meeting of the Hip Society. St. Louis, etc; CV Mosby Co, 1976:45-66.
7. **Eppright RH.** Dial osteotomy of the acetabulum in the treatment of dysplasia of the hip. *J Bone Joint Surg [Am]* 1975;57-A:1172.
8. **Ganz R, Klaue K, Vinh TS, Mast JW.** A new peri-acetabular osteotomy for the treatment of hip dysplasias: technique and preliminary results. *Clin Orthop* 1988;232:26-36.
9. **Trousdale RT, Ekkernkamp A, Ganz R, Wallrichs SL.** Periacetabular and intertrochanteric osteotomy for the treatment of osteoarthrosis in dysplastic hips. *J Bone Joint Surg [Am]* 1995;77-A:73-85.
10. **Ueda T, Tohkura A.** Evaluation of isokinetic hip strength after rotational acetabular osteotomy. *Nippon Seikeigeka Gakkai Zasshi* 1993;67:1105-13.
11. **Merle d'Aubigné R, Postel M.** Functional results of hip arthroplasty with acrylic prosthesis. *J Bone Joint Surg [Am]* 1954;36-A:451-75.
12. **Wiberg G.** Studies on dysplastic acetabula and congenital subluxation of the hip joint: with special reference to the complication of osteoarthritis. *Acta Chir Scand* 1939;83:Suppl. 58.
13. **Massie WK, Howorth MB.** Congenital dislocation of the hip: Part 1. Method of grading results. *J Bone Joint Surg [Am]* 1950;31-A: 519-31.
14. **Harry JD, Gross RH.** A quantitative method for evaluating results of treating Legg-Perthes syndrome. *J Pediatr Orthop* 1987;7:671-6.
15. **Leitz G, Reck R.** Necessarily disappointing results after triple-osteotomy in the dysplastic hip joint. *Arch Orthop Trauma Surg* 1979;95:271-3.
16. **Millis MB.** Congenital hip dysplasia: treatment from infancy to skeletal maturity. In: Tronzo RG, ed. *Surgery of the hip joint.* Vol. 1. 2nd ed, New York, Springer-Verlag, 1984;329-85.