

# THE THREE-DIMENSIONAL GEOMETRY OF THE PROXIMAL HUMERUS

## IMPLICATIONS FOR SURGICAL TECHNIQUE AND PROSTHETIC DESIGN

P. BOILEAU, G. WALCH

*From the Medical University Hospital of Nice and Lyon, France*

**We have studied the three-dimensional geometry of the proximal humerus on human cadaver specimens using a digitised measuring device linked to a computer. Our findings demonstrated the variable shape of the proximal humerus as well as its variable dimensions. The articular surface, which is part of a sphere varies individually in its orientation as regards inclination and retroversion, and it has variable medial and posterior offsets.**

These variations cannot be accommodated by the designs of most contemporary humeral components. Although good clinical results can be achieved with current modular and non-modular components their relatively fixed geometry prevents truly anatomical restoration in many cases.

To try to restore the original three-dimensional geometry of the proximal humerus, we have developed a new type of humeral component which is modular and adaptable to the individual anatomy. Such adaptability allows correct positioning of the prosthetic head in relation to an individual anatomical neck, after removal of the marginal osteophytes. The design of this third-generation prosthesis respects the four geometrical variations which have been demonstrated in the present study. These are inclination, retroversion, medial offset and posterior offset.

*J Bone Joint Surg [Br] 1997;79-B:857-65.*

*Received 8 January 1997; Accepted after revision 21 March 1997*

---

P. Boileau, MD

Department of Orthopaedic Surgery, Medical University of Nice-Hôpital de L'Archet, 151 Route de St-Antoine de Ginestière, 06200 Nice, France.

G. Walch, MD

Clinique Emilie de Vialar, 116 Rue Antoine Charrial, Lyon 69003, France.

Correspondence should be sent to Dr P. Boileau.

---

©1997 British Editorial Society of Bone and Joint Surgery  
0301-620X/97/57579 \$2.00

Clinical studies of total shoulder arthroplasty have shown that restoration of the normal anatomy of the proximal humerus is desirable. This affects the lever arms of the deltoid and rotator cuff in the vertical plane and soft-tissue balance in the horizontal plane.<sup>1-3</sup> Changes in this anatomy may produce abnormal kinematics by malpositioning the joint line and by moving the instant centres of rotation.<sup>4-6</sup> There may also be an effect on the fixation of the glenoid component from increased loads in the long term.<sup>2,7,8</sup>

Despite this, few studies have examined the detailed anatomy of the proximal humerus and these have usually focused on its dimensions rather than its three-dimensional geometry.<sup>9-15</sup> Our experience with shoulder arthroplasty has shown consistent difficulties in recreating the normal anatomy, and we have indicated in a previous cinéradiological study that active elevation of a prosthetic shoulder produces abnormal kinematics.<sup>16</sup>

We report a detailed anthropometric study of the geometry of the proximal humerus, suspecting that this may not be as simple as has been previously reported. We considered that the articular surface may show variable orientation and translation in both the coronal and axial planes.

### MATERIALS AND METHODS

We made surface measurements on fresh human cadaver specimens using a digitised measuring system to allow three-dimensional computerised modelling of the bones. There were three stages: first, we verified the sphericity of the cartilaginous surface, secondly we studied the distribution of the diameter and depth of the articular surface, and thirdly we defined both the orientation (inclination and retroversion) and location (possible anteroposterior and/or mediolateral offsets) of the articular surface.

From fresh Caucasian cadavers we obtained 65 humeri (32 left, 33 right; 26 paired) and dissected off all soft tissue, taking care to avoid damage to the articular cartilage. They came from 19 men and 20 women; their ages ranged from 67 to 95 years (mean 86 ± SD 13 years). We excluded specimens which showed any evidence of osteoarthritis, osseous pathology, or previous fractures.

A highly accurate three-dimensional digitised measuring



Fig. 1a

Apparatus used for the precision measurements (a) and the resulting three-dimensional image (b).

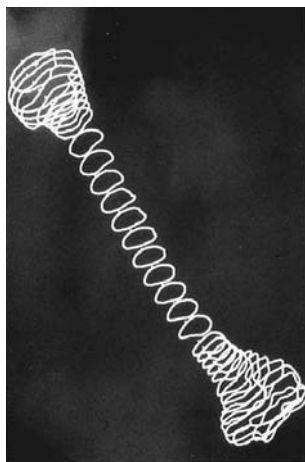


Fig. 1b

machine (Metrologic MTI; Metrologic Instruments, Meylan, France) was equipped with a special frame to hold a humerus (Fig. 1a), by supports at the humeral head and at the elbow, so that it could be rotated around its diaphyseal axis. After precalibration, surface measurements were made with a manual probe at rotations in  $10^\circ$  increments. This allowed parallel slices to be measured at every 5 mm at the

level of the proximal and distal epiphyses and every 10 mm along the shaft. The bones were then fixed in rotation for the measurement of points on the articular surface of the humeral head. A total of over 1200 points was digitised for each humerus.

The data were collected in a computer equipped with manual software (Métrosoft-3D; Metrologic Instruments, Meylan, France), which produced three-dimensional images (Fig. 1b). Manipulation on a CAD workstation then gave surface reconstructions and multiplanar reformatted images. The computer software could calculate precisely the diameter, thickness, inclination and retroversion and also model the proximal humerus using simple geometrical figures (Fig. 2a).

**The anatomical neck plane (C-D)** was that best fitting the periphery of the articular surface.

**The epiphyseal sphere** was that which best fitted the edges of the articular surface of the humeral head with its centre calculated (O).

**The metaphyseal cylinder** was the cylinder which best fitted the shape of the upper humeral shaft, with its axis at O'. This cylinder was arbitrarily limited to the proximal half of the bone because there is a change in curvature in the coronal plane half way down the humeral shaft at 10.3 to 15.8 cm from the top of the articular surface.

We defined five axes (Fig. 2a):

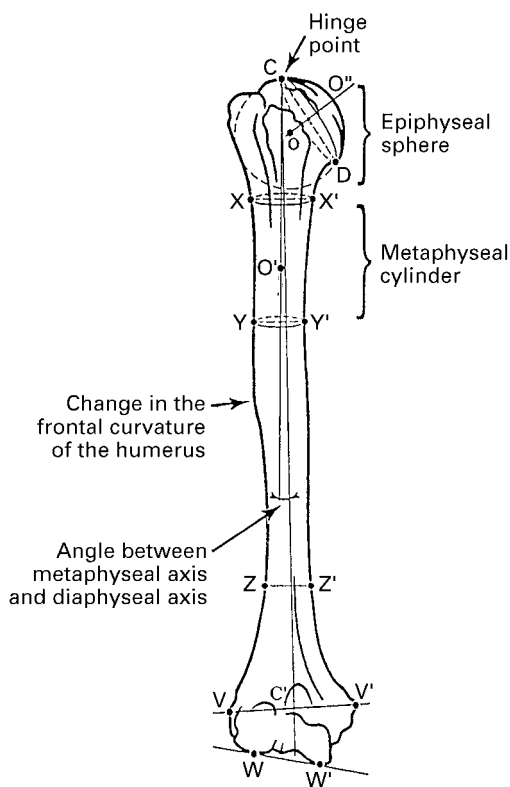


Fig. 2a

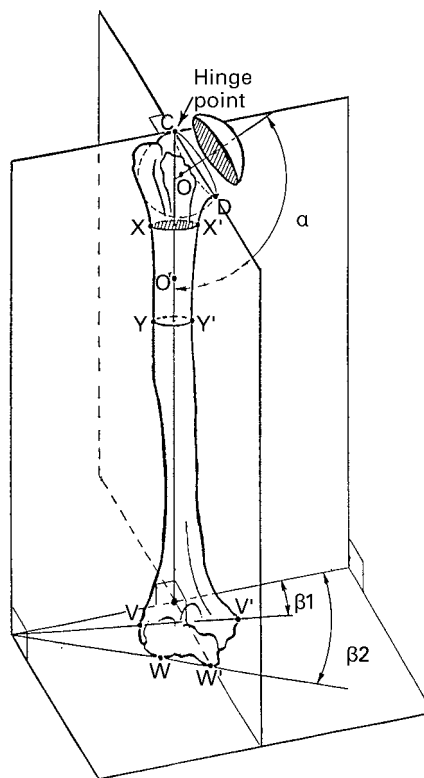


Fig. 2b

Figure 2a – Axes used to characterise the morphological factors: (1) humeral head axis; (2) diaphyseal axis; (3) metaphyseal axis; (4) transepicondylar axis; (5) tangent elbow axis. Figure 2b – Three-dimensional co-ordinate system (see text).

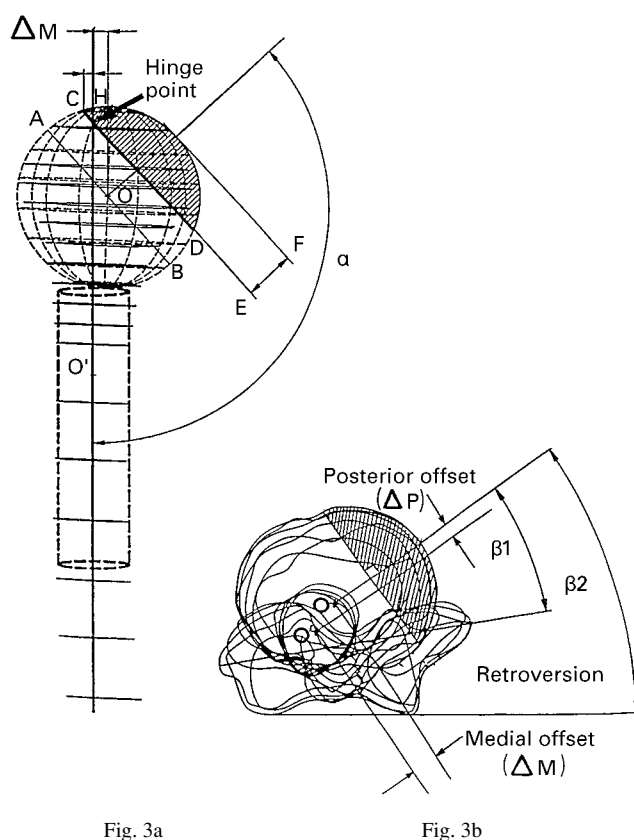


Figure 3a – Measurements in the frontal view: diameter of curvature (A-B); articular surface diameter (C-D); articular thickness (E-F); medial offset ( $\Delta M$ ); 'hinge-point' distance (C-H); inclination angle ( $\alpha$ ). Figure 3b – Anatomical measurements made in the axial view: retroversion angle related to the transepicondylar axis ( $\beta_1$ ) and to the tangent axis ( $\beta_2$ ). Medial offset ( $\Delta M$ ) and posterior offset ( $\Delta P$ ).

- 1) the humeral head axis ( $O-O''$ ) was defined as that perpendicular to the anatomical neck taken to the periphery of the articular cartilage;
- 2) the diaphyseal axis represented the arbitrary axis of rotation of the bones ( $C-C'$ );
- 3) the proximal metaphyseal or intramedullary axis is of interest because it represents the theoretical axis of the stem of a prosthesis ( $C-O'$ );
- 4) the transepicondylar axis was defined by a line joining the most medial and the most lateral extremities of the distal humerus ( $V-V'$ ); and
- 5) the tangent elbow axis was defined by a line parallel to the trochlea and the medial condyle ( $W-W'$ ).

All the morphological factors related to the orientation and location of the articular surface were calculated in relation to the proximal metaphyseal axis for inclination, anteroposterior translation and mediolateral translation, and to the transepicondylar and tangent axes for retroversion. We called the crossing point between the metaphyseal axis and the anatomical neck plane the **hinge point**.

The axes of reference for the three dimensions of space were then defined (Fig. 2b). The image of each proximal humerus was inclined until the proximal metaphyseal axis

was vertical, defining the inferosuperior axis. The images of the bones were then rotated around the proximal metaphyseal axis until the anatomical neck plane appeared as a line. The projection of this line on to a perpendicular to the already defined X axis resulted in a vector which defined the anteroposterior axis. The plane perpendicular to the X-Y plane defined the mediolateral axis. A three-dimensional co-ordinate axis system was thus established with its origin within the metaphyseal cylinder. All the measurements were made in accordance with these projections.

The anatomical humeral parameters measured by this procedure for each specimen included the following (Figs 3a and 3b):

- 1) the diameter of curvature of the articular surface of the humeral head measured in both coronal and axial planes (distance A-B);
- 2) the articular surface diameter in both coronal and axial planes, defined as the diameter of the articular surface at the level of the margin of the cartilage (distance C-D);
- 3) the articular surface thickness, defined as the perpendicular distance from the articular margin to the apex of the diameter of curvature (distance E-F);
- 4) the inclination angle between the proximal metaphyseal (intramedullary) axis and that perpendicular to the articular margin plane (angle  $\alpha$ );
- 5) the retroversion angle between a perpendicular to the articular margin plane and the transepicondylar (angle  $\beta_1$ ) or the tangent elbow axes (angle  $\beta_2$ );
- 6) the medial offset which is the perpendicular distance between the axial planes containing the centre of the epiphyseal sphere and the central axis of the metaphyseal cylinder ( $\Delta M$  = distance  $O-O'$  in the coronal plane);
- 7) the posterior offset which is the perpendicular distance between the coronal plane containing the centre of the epiphyseal sphere and that containing the central axis of the metaphyseal cylinder ( $\Delta P$  = distance  $O-O'$  in the axial plane); and
- 8) the hinge-point distance which is the distance between the axial plane containing the axis of the cylinder and the upper border of the articular surface (distance C-H).

To verify the sphericity of the humeral head we used the classical method of least-square optimisation,<sup>17</sup> defined as the thickness of a theoretical spherical shell with outer ( $D_1$ ) and inner ( $D_2$ ) theoretical diameters which would contain all digitised points within its thickness. The standard deviation of all data points is a measure of sphericity. For this study we accepted that a three-dimensional shell in which the difference between the two extreme diameters was less than 1 mm (or 2% of the average diameter), could be considered to be a true sphere ( $D_1-D_2 < 1$  mm).

Surface measurements were made on the outside of each humerus and it could be argued that these were less accurate than intramedullary measurements, and that fitting a cylinder to these data provided a poor geometrical model. To investigate this, we osteotomised ten humeri in the frontal plane and ten in the sagittal plane, then measured with a

**Table I.** Summary of the variables characterising the humeral specimens

Dimensions	Mean	Standard deviation	Minimum	Maximum
Diameter of curvature (humeral head diameter) (mm)	46.2	5.4	37.1	56.9
Articular surface diameter (mm)	43.3	4.3	36.5	51.7
Articular surface thickness (mm)	15.2	1.6	12.1	18.2
Inclination (degrees)*	129.6	2.9	123.2	135.8
Retroversion (transepicondylar axis) (degrees)	17.9	13.7	-6.7	47.5
Retroversion (tangent elbow axis) (degrees)	21.5	15.1	-10.3	56.5
Posterior offset (mm)*	2.6	1.8	-0.8	6.1
Medial offset (mm)*	6.9	2.0	2.9	10.8

\* inclination, posterior offset and medial offset have been calculated related to the metaphyseal axis or theoretical stem axis of a humeral component

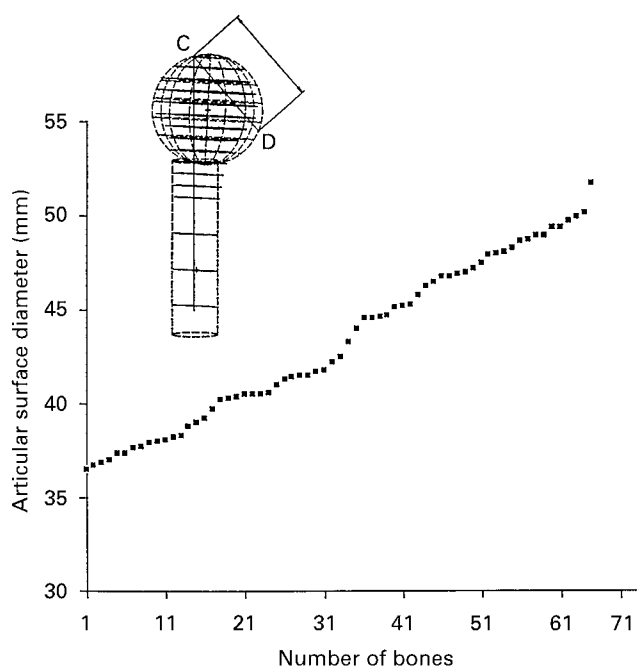


Fig. 4

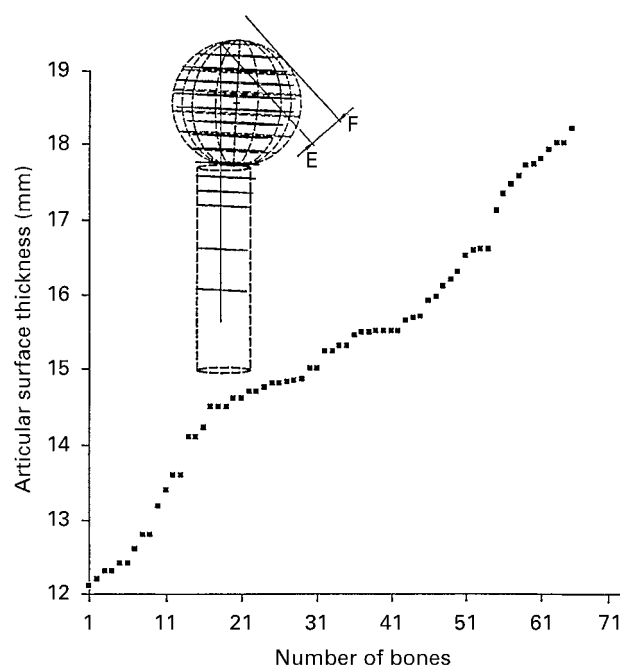


Fig. 5

Figure 4 – Distribution of diameters of the articular surface. Figure 5 – Distribution of the depth of the articular surface.

calliper at both the inside and outside of the proximal part of the bones. The margins of the cortical bone were nearly parallel with less than 1 mm of difference. The maximum deviation of the cylinder diameter was less than 5 mm from the top to the bottom of the cylinder. This confirmed that extramedullary were comparable with intramedullary measurements, and that a cylinder is an acceptable representation of the geometry of the humeral shaft. Even if the humeral shaft is not a true cylinder, its axis and the theoretical stem axis can be defined. Our use of only the proximal half of the humerus to define it is justified on two facts: first, a prosthetic stem is usually located in the proximal half and secondly, we had observed, from both the computer-generated pictures and our coronal sections of the humeri, that there is a change in curvature of the shaft in the frontal plane below the proximal 13 cm (see Fig. 2a).

The digitising machine was accurate to the order of

10  $\mu$ m, considered to be insignificant for this application. To determine observer variability, we chose ten specimens randomly. They were independently digitised by two different observers, and the measurements were repeated three weeks later in a blinded format. Analysis of variance showed that the standard deviation for repeat readings by one observer and between two observers was less than 1 mm for linear measurements and less than 1° for angular measurements.

## RESULTS

Table I gives a summary of our results. Our important findings are not the standard values but the large variations in the measured parameters.

The diameter of curvature varied from a minimum of 37.1 mm to a maximum of 56.9 mm (mean 46.2). The

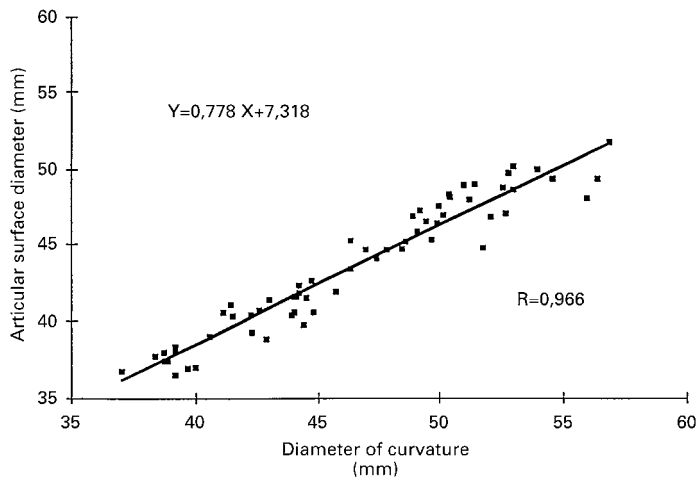


Fig. 6

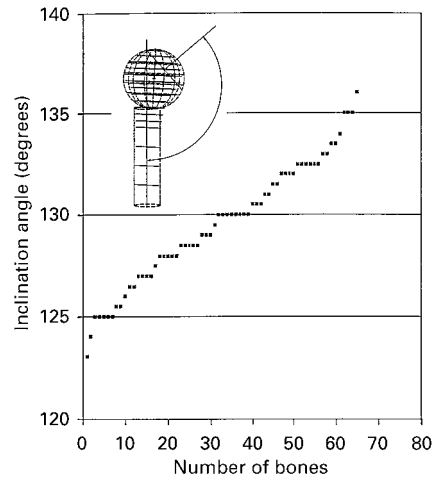


Fig. 7

Figure 6 – Relationship between the diameter and the depths of the articular surface. Figure 7 – Distribution of the inclination angle in relation to the metaphyseal axis.

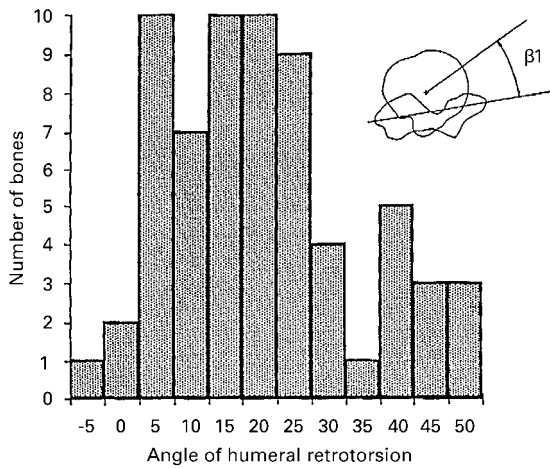


Fig. 8

Distribution of the retroversion angle in relation to the trans-epicondylar axis.

difference between the two extreme diameters for each single humeral sphere was less than 1 mm in 88.2% of the specimens, showing that most formed a true sphere as defined above.

The articular surface diameters (distance C-D) are shown in Figure 4 and the distribution of the depth of the humeral head (distance E-F) in Figure 5. We found a strong linear correlation between articular surface diameter and this ‘thickness’ of the humeral head. Regression analysis determined the equation of the regression line as  $y = 0.78x + 7.32$ , where  $y$  was the articular surface diameter and  $x$  was the thickness of the humeral head ( $r = 0.96$ ; Fig. 6).

The distribution of the inclination angles of the articular surface with respect to the proximal metaphyseal axis (angle  $\alpha$ , neck-shaft angle) is shown in Figure 7, and the distribution of the retroversion angles with respect to the transepicondylar axis (angle  $\beta 1$ ) in Figure 8.

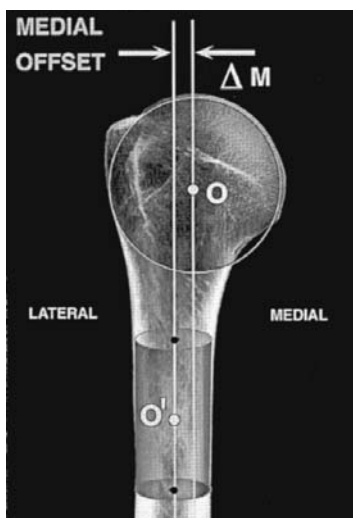


Fig. 9a

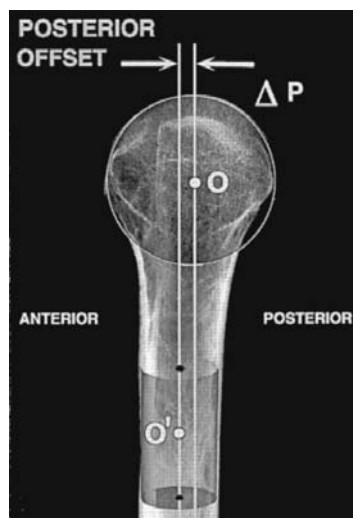


Fig. 9b

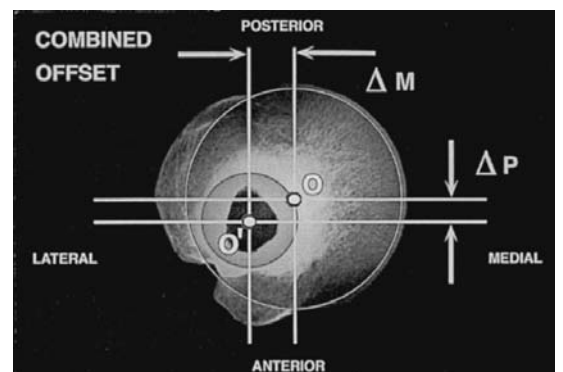


Fig. 9c

Translation of the articular head surface related to the theoretical stem axis shown on radiographs: a) medial offset; b) posterior offset; c) combined offset.

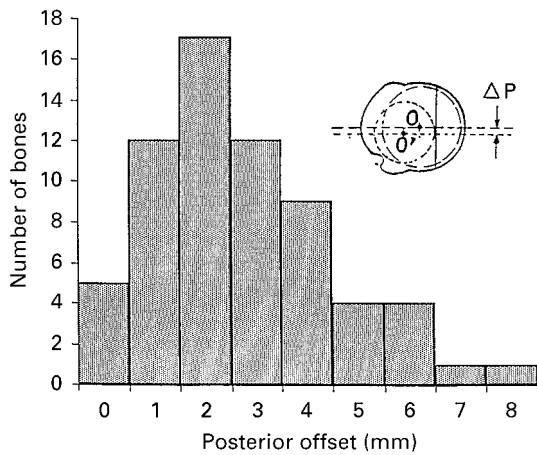


Fig. 10

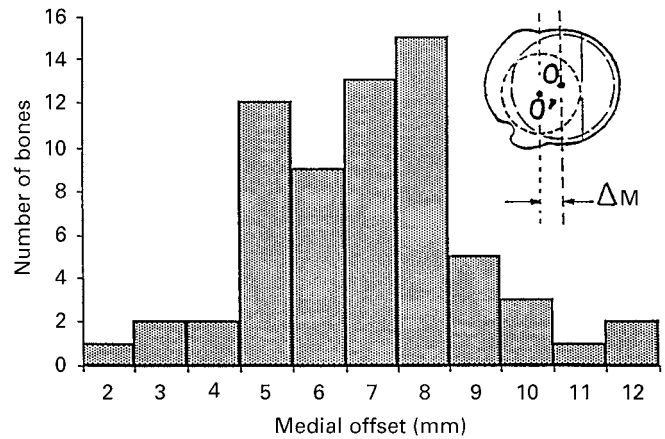


Fig. 11

Figure 10 – Distribution of the posterior offset of the centre of the humeral head relative to the metaphyseal axis. Figure 11 – Distribution of the medial offset of the centre of the humeral head relative to the metaphyseal axis.

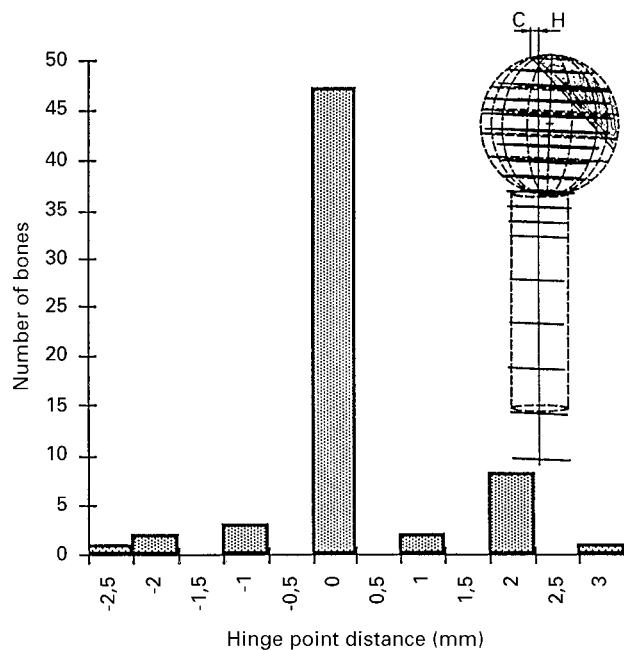


Fig. 12

Distribution of the 'hinge-point' distance (C-H). The intramedullary axis intersects the plane of the anatomical neck (C-D) almost constantly at point C (top of the articular surface). The distance C-H was less than 1 mm in 72.3% of the bones.

The epiphyseal sphere did not lie centrally on the base of the metaphyseal cylinder but was offset in both planes, leading to a combined, medial and posterior, offset of the articular surface (Fig. 9). The posterior offset averaged 2.6 mm (95% CI -0.8 to 6.1), with a distribution shown in Figure 10. The medial offset averaged 6.9 mm (95% CI 2.9 to 10.8) (Fig. 11).

The distance between the theoretical stem axis and the geometrical centre of the articular surface, the hinge-point

distance, was less than 1 mm in 72.3% of the humeri, (Fig. 12).

DISCUSSION

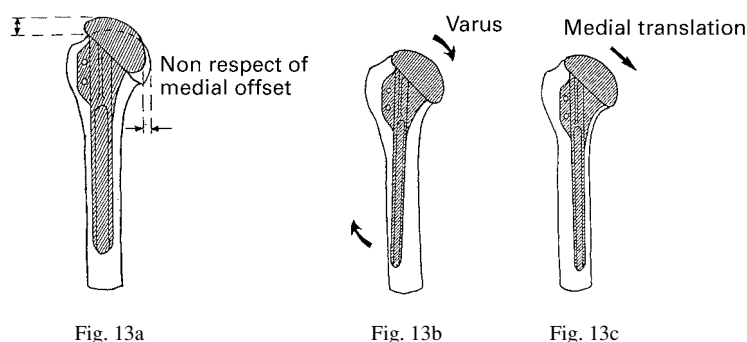
Our study has emphasised that the shape of the proximal humerus is more important than its dimensions, because of its variable orientation (inclination and retroversion) and its variable medial and posterior offset. This suggests that restoration of normal anatomy during arthroplasty may be difficult with the relatively fixed geometry of existing prosthetic systems. Failure to match the shape has potential biomechanical consequences due to malposition of the joint line, moving the instant centres of rotation or both.<sup>2,3,5,16,18,19</sup> The degree of precision needed for the reconstruction of the proximal humerus is unknown, but other work suggests that it has fairly tight limits. Fischer et al<sup>4</sup> have shown that if the centre of curvature is displaced by 20% of its radius (5 mm for an average radius of 25 mm), the lever arm of the rotator cuff will be altered by 20%. Poor prosthetic design or poor surgical technique is known theoretically to lead to problems (Table II),<sup>1, 20-23</sup> and alteration of the bony anatomy may also lead to eccentric loading at the periphery of the glenoid, increasing glenoid wear and glenoid loosening.<sup>2,7,8</sup>

**Coronal plane.** In the coronal plane there are two variables which may interfere with the positioning of the articular surface: inclination angle and medial offset. The intersection point or hinge point which we describe between the metaphyseal axis and the superior margin of the articular head surface forms a useful surgical guide when performing a hemiarthroplasty. The medullary canal of the humerus should be reamed starting at a point which is lateral on the cut surface. The mean inclination angle of 130° in our study corresponds to those previously reported,<sup>9,10,11,15</sup> but the average value is completely relative; its considerable

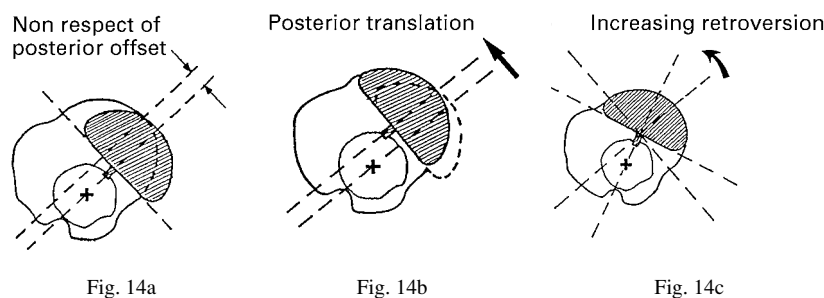
**Table II.** Variable orientation (inclination and retroversion) and location (medial offset and posterior offset) of the articular surface of the humeral head, with the pathological consequences and the surgical possibilities of control when using a fixed-design humeral component

	Articular head surface orientation and location	Potential pathological consequences of error	Surgeon-controllable variables*
Coronal plane	{ Inclination Medial offset	{ Subacromial impingement (superior "bulging" of the prosthetic head) Glenoid (posterior) impingement (inferior "sliding" of the prosthetic head)	{ Varus/valgus and / or Mediolateral translation
Axial plane	{ Retroversion Posterior offset	{ Coracoid impingement (anterior "bulging" of the prosthetic head) Anteroposterior instability (abnormal rotation and/or anteroposterior translation of the humeral component)	{ Anteversion/retroversion and / or Anteroposterior translation

\* these possibilities are partially or totally reduced with cementless, close-fitting humeral components and/or humeral components with stems which are too long



Two methods of correcting medial offset surgery (a) by implanting the prosthesis with some varus (loose-fit stem) (b) or implanting the prosthesis with some medial translation (loose-fit stem) (c).



Two methods of correcting posterior offset at surgery (a) by posterior translation of the prosthetic head (loose-fit stem) (b) or increasing retroversion with a bone cut in excessive version (c).

variation in individuals must be kept in mind. Most prostheses limit the potential for reproducing the original anatomy: a humeral cut at  $140^\circ$  inclination in a patient who originally had only  $125^\circ$  inclination will displace the centre of rotation proximally and alter the kinematics.<sup>8,24</sup> A more useful guide is the orientation of a humeral component to the original true anatomical neck: this may be more appropriate for a specific shoulder than routine orientation to the same inclination.<sup>24,25</sup> The variable medial offset of the articular surface found in our study has not been reported previously – this too may create difficulties in restoring the original bony anatomy with a shoulder prosthesis of fixed design.<sup>25</sup>

**Axial plane.** In the axial plane there are also two variables: the retroversion angle and the posterior offset. The low average retroversion angle which we found ( $17.9^\circ$ ) confirms other anatomical studies by Broca,<sup>26</sup> Krahl and Evans<sup>27</sup> and Roberts et al<sup>28</sup> who reported values of  $16$ ,  $15.6$  and  $21.4^\circ$ , respectively. More importantly, however, retro-

version of the proximal humerus is highly variable, ranging from  $-6.7^\circ$  to  $47.5^\circ$ . Again, this means that anatomical reconstruction of the retroversion angle should be individual, following the landmarks of the true anatomical neck.<sup>29,30</sup> Posterior offset also varies, ranging from  $-0.8$  to  $6.1$  mm. Roberts et al,<sup>28</sup> also using an extramedullary method, reported a posterior offset from  $0$  to  $12$  mm, but Ballmer et al,<sup>6</sup> using an intramedullary method, found an offset ranging from  $3$  mm anterior to  $4$  mm posterior. Our study, like those of Roberts et al<sup>28</sup> and Ballmer et al,<sup>6</sup> has shown that part of what is called retroversion is actually due to posterior offset; this should be taken into consideration by shoulder surgeons.

**Surgical relevance.** The monobloc prosthesis developed by Neer et al<sup>1</sup> for the humeral component remains the 'gold standard' associated with excellent and good results at long-term follow-up. The first-generation shoulder prosthesis met the needs of many patients, but offered only a mid-range of sizes and did not exactly reproduce the

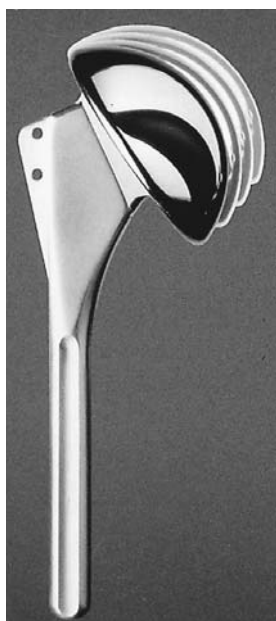

Fig. 15a




Fig. 15b

An adaptable prosthesis: a) adaptation of inclination by a system of variable necks between the stem and the head, b) adaptation of medio-lateral and anteroposterior offset through an eccentric indexing system.

coronal and axial geometry of the proximal humerus.<sup>15,31</sup>

Our study helped us to understand how surgical technique can compensate for the anatomical variation of proximal humeri by paying meticulous attention to details of placement (Table II). Surgical experience and judgement are required for the accurate orientation and location of the prosthesis.<sup>7,24,32</sup> For example, variation in medial offset or inclination or both may be compensated for by choosing a smaller stem and increasing the varus or medial translation, or both, for the humeral component<sup>24</sup> (Fig. 13). Such varus or medial positioning of the humeral component, however, may tighten some of the soft tissues by increasing separation between their glenoid and humeral attachments, and may therefore be of questionable value.<sup>33</sup> When a humeral head prosthesis seats eccentrically too anterior in the axial plane there are two technical possibilities: one is to choose a smaller stem to allow posterior translation and centralisation at the time of cementing; the other is to resect more bone posteriorly, limited by the rotator-cuff insertion, to allow an increase in prosthetic retroversion (Fig. 14). This may explain why the recommended surgical retroversion angle is higher at 30 to 40° than the anatomical angle.<sup>34-36</sup> Moving the prosthesis to face more posteriorly, however, may not restore the balance between the anterior and posterior structures and may also be questionable.<sup>8,29,33</sup>

The current proliferation of second-generation shoulder prostheses offers modular implants with a greater selection of sizes for both the prosthetic head and the stem. This choice may help the surgeon to match the variation in size

of articular surface and improve the soft-tissue balancing.<sup>6,7,18,33</sup> The range of stems aims to allow better primary stabilisation and better fixation, but filling the medullary canal with a prosthetic stem may prevent accurate reproduction of the anatomical model by placing the head eccentrically. The close fit of a cementless stem will dictate the position of the prosthetic head and make it much more difficult, if not impossible, to match the medial and posterior offset and so achieve coverage of the bone cut. As emphasised by Ballmer et al<sup>6</sup> the fit of such a prosthesis eliminates all but two of the six degrees of freedom, leaving only the depth of insertion and the rotation of its stem to allow adjustment.<sup>6</sup> A loosely fitting prosthesis offers more possibilities as regards alignment but its fixation may be questionable. Stem length is another limiting factor: too long a stem may prevent insertion with enough varus, for example, to compensate for a large medial offset, because of the change in curvature of the proximal diaphysis which we observed.

Good clinical results can be achieved with both the modular and non-modular components that are available, but their relatively fixed geometry means that they cannot be truly anatomical when compared with the findings of our study. The shape of the proximal humerus is much more variable than most contemporary designs of humeral component suggest or can accommodate.<sup>24,25,32</sup>

To try to restore the original three-dimensional geometry, we have developed a new type of humeral component (Aequalis Prosthesis; Tornier Inc, Saint-Ismier, France).<sup>37</sup> This third-generation shoulder prosthesis is not only modular but also adaptable to the individual bony anatomy. Prosthetic adaptability, a new concept in shoulder arthroplasty, allows the correct placement of the prosthetic head, with the restoration of normal glenohumeral anatomy and kinematics. The prosthesis also fills the medullary canal with the stem to optimise fixation. The design of this new type of prosthesis allows the individual anatomy to be reproduced (Fig. 15) and incorporates variable inclination, using variably-angled neck components between the stem and the prosthetic head. Individual head retroversion is provided by osteotomy of the articular surface after removal of the crown of osteophytes. The design provides variable posterior and medial offset of the articular surface through an eccentric indexing system (Fig. 15). While soft-tissue balancing is achieved by performing an anterior release, the correct spatial positioning of the humeral head relative to the humerus results in 'bony balancing'. This combination should result in normal glenohumeral kinematics and decrease abnormal eccentric loads on the glenoid component.

The authors wish to thank Y. A. Ratron, D. Perret and F. Ducret and for their technical assistance, C. Gerber, MD and J. J. P. Warner, MD for providing helpful discussions and D. Boileau, MD for her help in preparing the final manuscript.

One or more of the authors have received or will receive benefits for personal or professional use from a commercial party related directly or indirectly to the subject of this article.

## REFERENCES

1. Neer CS II, Watson KC, Stanton FJ. Recent experience in total shoulder replacement. *J Bone Joint Surg [Am]* 1982;64-A:319-37.
2. Figgie HE III, Inglis AE, Goldberg VM, et al. An analysis of factors affecting the long term results of total shoulder arthroplasty in inflammatory arthritis. *J Arthroplasty* 1988;3:123-30.
3. Rietveld ABM, Daanen HAM, Rezing PM, Obermann WR. The lever arm in glenohumeral abduction after hemiarthroplasty. *J Bone Joint Surg [Br]* 1988;70-B:561-5.
4. Fischer LP, Carret JP, Gonon GP, Dimnet J. Étude cinématique des mouvements de l'articulation scapulo-humérale (Articulatio Humeri). *Rev Chir Orthop* 1977;63(Suppl II):108-12.
5. Friedman RJ. Biomechanics of the shoulder following total shoulder replacement. In: Post M, Morrey BF, Hawkins RJ, eds. *Surgery of the shoulder*. St Louis, Mosby-Year Book, 1990:263-6.
6. Ballmer FT, Sidles JA, Lippitt SB, Matsen FA, III. Humeral head prosthetic arthroplasty: surgically relevant geometric considerations. *J Shoulder Elbow Surg* 1993;2:296-304.
7. Fenlin JM, Vacaro A, Andreichik D, Lin S. Modular total shoulder: early experience and impressions. *Seminars in Arthroplasty* 1990;Vol. 1:2:102-11.
8. Pearl ML, Volk AG. Coronal plane geometry of the proximal humerus relevant to prosthetic arthroplasty. *J Shoulder Elbow Surg* 1996;5:320-6.
9. Fick R. *Anatomie und mechanik der gelenke*. Verlag von Gustav Fischer, Jena, 1904:171-4.
10. Strasser H. Das Schultergelenk Die obere Extremität. In: *Lerbuch der Muskel und Gelenkmechanik*. Berlin: Verlags von Julius Springer 1917:17-21.
11. Steindler A. Mechanics of shoulder arm complex. In: *Kinesiology of the human body under normal and pathological conditions*. Springfield, Illinois: C.C. Thomas 1936:452-3.
12. Maki S, Gruen T. Anthropometric study of the glenohumeral relationships. *Trans Orthop Res Soc* 1976;1:173.
13. Clarke IC, Gruen TAW, Sew Hoy A, Hirschowitz D, Maki S, Amstutz HC. Problems in gleno-humeral surface replacements: real or imagined? *Engin Med* 1979;8:161-75.
14. Ishibashi T, Mikasa M, Fukuda H. A new humeral prosthesis for the Japanese. In: Post M, Morrey BF, Hawkins RJ. *Surgery of the shoulder*. St Louis, Mosby-Year Book, 1990:273-81.
15. Iannotti JP, Gabriel JP, Schneck SL, Evans BG, Misra S. The normal glenohumeral relationships: an anatomical study of one hundred and forty shoulders. *J Bone Joint Surg [Am]* 1992;74-A:491-500.
16. Boileau P, Walch G, Liotard JP. Cineradiographic study of active elevation of the prosthetic shoulder. *J Orthop Surg* 1992;6:351-9.
17. Soslowsky LJ, Flatow EL, Bigliani LU, Mow VC. Articular geometry of the glenohumeral joint. *Clin Orthop* 1992;285:181-90.
18. Harryman DT, Sidles JA, Harris SI, Lippitt SB, Matsen FA III. The effect of articular conformity and the size of the humeral head component on laxity and motion after glenohumeral arthroplasty: a study in cadavera. *J Bone Joint Surg [Am]* 1995;77-A:555-63.
19. Jobe CM, Iannotti JP. Limits imposed on glenohumeral motion by joint geometry. *J Shoulder Elbow Surg* 1995;4:281-5.
20. Gerber C, Terrier F, Zehnder R, Ganz R. The subcoracoid space: an anatomic study. *Clin Orthop* 1987;215:132-8.
21. Dines DM, Warren RF, Inglis AE, Pavlov H. The coracoid impingement syndrome. *J Bone Joint Surg [Br]* 1990;72-B:314-6.
22. Walch G, Boileau P, Noel E, Donnell ST. Impingement of the deep surface of the supraspinatus tendon on the posterosuperior glenoid rim: an arthroscopic study. *J Shoulder Elbow Surg* 1992;1:238-45.
23. Moeckel BH, Altcheck DW, Warren RF, Wickiewicz TL, Dines DM. Instability of the shoulder after arthroplasty. *J Bone Joint Surg [Am]* 1993;75-A:492-7.
24. Boileau P, Walch G. Varus shoulder prosthesis: error or necessity? *J Shoulder Elbow Surg* 1996;S62:186.
25. Walch G, Boileau P. Morphological study of the humeral proximal epiphysis. *J Bone Joint Surg [Br]* 1992;74-B:Suppl I:14.
26. Broca P. La torsion de l'humérus et le tropomètre, instrument destiné à mesurer la torsion des os. (rédigée par L. Mamouvier). *Rev d'Anthrop* 1881;2ème série 4:198-210, 386-423, 1577-92.
27. Krahl VE, Evans FG. Humeral torsion in man. *Am J Phys Anthropol* 1945;3:229-53.
28. Roberts SNJ, Foley APJ, Swallow HM, Wallace WA, Coughlan DP. The geometry of the humeral head and the design of prostheses. *J Bone Joint Surg [Br]* 1991;73-B:647-50.
29. Boileau P, Walch G, Mazzoleni N, Urien JP. In vitro study of humeral head retroversion. *J Shoulder Elbow Surg* 1993;2:part 2:S12.
30. Pearl ML, Volk AG. Retroversion of the proximal humerus in relationship to prosthetic replacement arthroplasty. *J Shoulder Elbow Surg* 1995;4:286-9.
31. Neer CS II. Glenohumeral arthroplasty. In: *Shoulder reconstruction*. Philadelphia: WB Saunders 1990:146-60.
32. Boileau P, Walch G. The combined offset (medial and posterior) of the humeral sphere. *J Shoulder Elbow Surg* 1994;3:6.
33. Collins DN, Harryman DT II, Lippitt SB, Jackins SE, Matsen FA III. The technique of glenohumeral arthroplasty. *Techniques Orthop* 1991;6:43-59.
34. Ovesen J, Nielsen S. Prosthesis position in shoulder arthroplasty: a cadaver study of the humeral component. *Acta Orthop Scand* 1985;56:330.
35. Randelli M, Gambrioli PL. Glenohumeral osteometry by computed tomography in normal and unstable shoulders. *Clin Orthop* 1986;208:151-6.
36. Kronberg M, Broström L-A, Söderlund V. Retroversion of the humeral head in the normal shoulder and its relationship to the normal range of motion. *Clin Orthop* 1990;253:113-7.
37. Boileau P, Walch G. Adaptabilité et modularité au cours des prothèses d'épaule. *Acta Orthop Belg* 1995;61:Suppl 1:49-61.