

LOWER-LIMB LENGTHENING IN SHORT STATURE

AN ELECTROPHYSIOLOGICAL AND CLINICAL ASSESSMENT OF PERIPHERAL NERVE FUNCTION

ALBERTO POLO, ROBERTO ALDEGHERI, ANTONINO ZAMBITO, GIAMPAOLO TRIVELLA, PAOLO MANGANOTTI, DOMENICO DE GRANDIS, NICOLA RIZZUTO

From the University of Verona, Italy

We assessed peripheral nerve function during and after lower-limb lengthening by callotasis in 14 patients with short stature, using motor conduction studies.

Four patients with short stature of varying aetiology showed unilateral and one showed bilateral weakness of foot dorsiflexion. Both clinical and electrophysiological abnormalities consistent with involvement of the peroneal nerve were observed early after starting tibial callotasis. There was some progressive electrophysiological improvement despite continued bone distraction, but two patients with Turner's syndrome had incomplete recovery. A greater percentage increase in tibial length did not correspond to a higher rate of peroneal nerve palsy. The function of the posterior leg muscles and the conduction velocity of the posterior tibial nerve were normal throughout the monitoring period.

The F-wave response showed a longer latency at the end of the bone distraction than in basal conditions; this is probably related to the slowing of conduction throughout the entire length of the nerve.

J Bone Joint Surg [Br] 1997;79-B:1014-18.

Received 1 July 1996; Accepted after revision 3 July 1997

Callotasis has become a widely used and accepted procedure for lengthening of the lower limbs in patients with short stature.^{1,2} Extensive lengthening in such patients may be accompanied by mechanical and neurological impairment in the lower limbs³ and different, and sometimes contrasting, treatment procedures have been suggested based on personal experience rather than on clinical and experimental data. The extent of the lengthening and the surgical technique are important factors in the aetiology of neurological complications.⁴⁻⁷ The sensitivity of the nerve to damage is related to its anatomical course and to its resistance to stretching.

We have studied the muscles and nerves in close contact with the lengthened bone segments in subjects with short stature of varying aetiology. We used both conventional methods (nerve-conduction velocity, needle EMG) and analysis of the F-wave (recurrent response). The latter is useful for assessing the most proximal segment since it results from antidromically activated motor neurones in the anterior horn of the spinal cord.⁸ It is important for studying motor disturbances in multiradicular entrapment of the lumbar spine.⁹

PATIENTS AND METHODS

We studied 14 patients affected with short stature (Table I): six had achondroplasia (AC), five had constitutional short stature (SS), and three had Turner's syndrome (TS). There were seven males and seven females with a mean age of 18.5 years (13 to 22). We performed MRI of the lumbosacral canal in AC patients to exclude the presence of spinal stenosis.

Operative technique. This has been described in detail elsewhere.^{2,10} Both femur and tibia are lengthened using unilateral external fixators (Orthofix; Orthofix SRL, Busso-lengo-Verona, Italy). We use the 'crossover' procedure in which the right femur and left tibia are lengthened first, and this is followed by lengthening of the left femur and right tibia. Distraction starts about ten days after surgery and proceeds at a rate of 0.25 mm, four times daily. The distraction rate can be changed in relation either to bone formation or functional problems.

A. Polo, MD, Neurologist
P. Manganotti, MD, Neurologist
N. Rizzuto, MD, Professor of Neurology
Dipartimento di Scienze Neurologiche e della Visione, Sezione di Neurologia, Università di Verona, Policlinico Borgo Roma, 37134 Verona, Italy.

R. Aldegheri, MD, Professor of Orthopaedics
A. Zambito, MD, Psychiatrist
G. Trivella, MD, Orthopaedic Surgeon
Clinica Ortopedica, Università di Verona, Verona, Italy.

D. De Grandis, MD, Neurologist
Reparto di Neurologia, Arcispedale S. Anna, Corso della Giovecca 203, 44100 Ferrara, Italy.

Correspondence should be sent to Dr A. Polo.

©1997 British Editorial Society of Bone and Joint Surgery
0301-620X/97/67912 \$2.00

Table I. Details of the 14 patients with short stature of varying aetiology

Case	Age (yr)	Height (cm)		Lengthening (cm; %)	
		Basal	Final	Femur	Tibia
Achondroplasia					
1 M	18	120	144	12 (39)	12 (46)
2 M	13	122	150	13.5 (60)	12.5 (64)
3 M*	22	119	144	12.5 (51)	12.5 (66)
4 F	19	129	147.5	10 (33)	8.5 (35.5)
5 M	14	122	153	14.5 (50)	15 (78)
6 F*	14	118	140	10.5 (43)	10.5 (55)
Mean ± sd	16.6 ± 3.5	121.6 ± 3.9	146.4 ± 4.7	12.2 (46) ± 1.7 (9.6)	11.8 (57.4) ± 2.2 (15.2)
Short stature					
7 M	17	154	168	7.5 (21)	6.5 (22)
8 M	19	164	171.5	2.5 (6)	5 (14)
9 F	21	143	155.5	7 (18)	5.5 (18)
10 F	21	151	160	5.5 (13)	3.5 (11)
11 M*	19	157	172	8 (19)	7 (20)
Mean ± sd	19.4 ± 1.6	153.8 ± 7.7	165.4 ± 7.3	6.1 (15.4) ± 2.2 (6.1)	5.5 (17) ± 1.4 (4.5)
Turner's syndrome					
12 F*	20	132	145.5	6.5 (18)	7 (26)
13 F	19	136	152	6.5 (18)	9.5 (34)
14 F*	17	138	157	9 (23)	10 (37)
Mean ± sd	18.6 ± 1.5	135.5 ± 3.1	151.5 ± 5.7	7.3 (19.7) ± 1.4 (2.9)	8.8 (32.3) ± 1.6 (5.7)

* patients affected by foot weakness

Electrophysiological study. We performed motor conduction studies according to standard protocols for clinical assessment.¹¹ Both the posterior tibial and common peroneal nerves were stimulated on both sides. The distal latency and amplitude of the compound muscle action potential (C-MAP) and motor conduction velocity (MCV) were determined under basal conditions and during the different phases of limb lengthening. Two recordings were obtained in the first stage, mid-way, and at the end of the distraction period. Similar recordings were made in the second-stage lengthenings. The electrophysiological assess-

ment was also performed at about six months after the consolidation period (control 1) and finally six months later (control 2) (Fig. 1).

The F-wave response was elicited by stimulating the common peroneal and tibial posterior nerves at the ankle while recording from the extensor digitorum brevis (EDB) and flexor hallucis brevis (FHB) muscles. The analysis time was 100 ms after each stimulus with the acquisition signal filtered through a band-pass of 200 Hz to 5 KHz. The mean latency of the F-wave was calculated on the averaged rectified mean of at least 20 consecutive responses (Fig. 2).

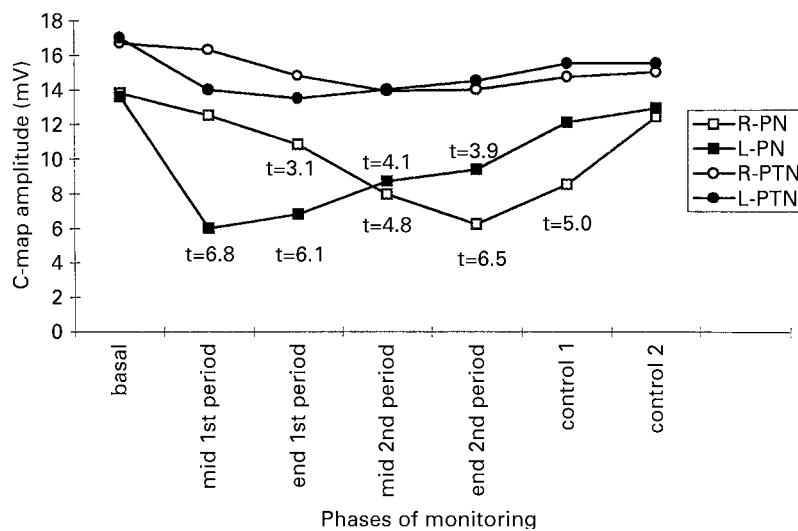


Fig. 1

Changes in amplitude of compound muscle action potentials (C-MAP) during the different phases of limb lengthening in patients with no clinical defects. Measurement of the mean amplitude was calculated from EDB and FHB after distal stimulation of the peroneal and posterior tibial nerves, respectively under basal conditions. The variation occurring in each monitoring phase was compared with the basal value to establish the statistical difference (R, right; L, left; PN, peroneal nerve; PTN, posterior tibial nerve).

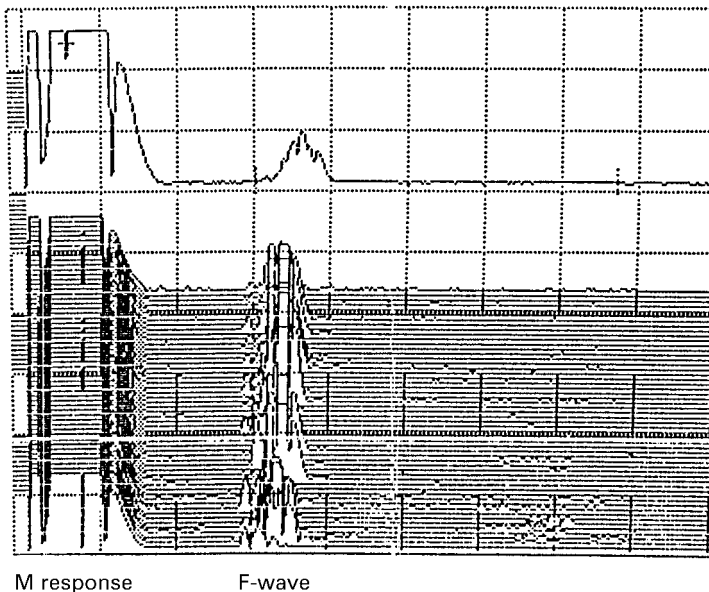


Fig. 2

M response and F-wave recorded from FHB after maximal stimulation of the posterior tibial nerve at the ankle. Fifty consecutive stimuli at 0.8 c/s were administered and the rectified traces superimposed. The single trace in the upper part of the grid shows the averaged potentials: the latency of the F-wave is measured at the onset of the response (calibration: 10 ms/div, 0.2 mV/div).

Needle EMG was performed in selected muscles of the legs including tibialis anterior (TA), EDB, peroneus longus (PL) and gastrocnemius medialis (GM). Insertional and spontaneous activity was recorded as was motor-unit recruitment during voluntary contraction.

The values in basal conditions were taken as control values and intrasubject variations were analysed. Data were analysed statistically using analysis of variance (ANOVA) with the Bonferroni *t*-test. We performed linear regression analysis to establish correlations, if any, between F-wave latency and the height of the patients.

RESULTS

The distal latency of the C-MAP from the peroneal nerve was significantly longer in SS than in AC ($t = 5.719$, $p < 0.001$) or TS ($t = 2.446$, $p = 0.013$), but in AC there was a shorter latency than in TS ($t = 2.446$, $p = 0.026$). The distal latency of the C-MAP from the posterior tibial nerve was longer in SS than in AC ($t = 8.490$, $p < 0.001$) or in TS ($t = 5.326$, $p < 0.001$); in AC there was a shorter latency than in TS ($t = 3.131$, $p = 0.006$).

The MCV and the amplitude of the distal C-MAP from both posterior tibial and peroneal nerve stimulation showed no statistically significant differences between the groups. The F-wave latency from the peroneal nerve correlated with height. Linear regression analysis in AC showed $r = 0.562$, $p = 0.036$, in SS $r = 0.814$ and $p = 0.004$, and in TS $r = 0.760$ and $p = 0.006$. The F-wave latency from the posterior tibial nerve also correlated with height. By linear regression analysis: AC, $r = 0.521$, $p = 0.044$; SS, $r = 0.742$, $p = 0.006$; and TS, $r = 0.610$, $p = 0.008$.

Monitoring of bone lengthening. Some weakness of foot dorsiflexion was seen in five patients (AC, cases 3,6; SS, case 11; TS, cases 12,14) after ipsilateral tibial callotaxis; one TS patient was bilaterally affected. Recordings after

surgery showed that all patients had a greatly reduced (< 1 mV) C-MAP amplitude from the left EDB muscle. Needle EMG showed signs of denervation in muscles innervated by the common peroneal nerve.

All patients had some progressive recovery from nerve lesions, both clinically and electrophysiologically, and eventually, the C-MAP amplitude reverted to normal. Larger numbers of polyphasic motor units, in both the TA and PL, were the only residual EMG abnormality. This observation is consistent with the theory that this 'EMG abnormality' indicates reinnervation.

In two TS patients the abnormalities did not settle even after removal of the fixator with persistent signs of chronic denervation on EMG and weakness of foot dorsiflexion at the latest review.

Six patients did not complain of any neurological symptoms and objective evaluation excluded sensorimotor defects; four other patients had a unilateral unaffected side. The results of electrophysiological monitoring are shown in Figure 1. During the first lengthening, while the femur was being distracted, the mean amplitude of the distal C-MAP of the EDB was found to be significantly reduced only in the late recording ($t = 3.1$). There was marked reduction in the mean C-MAP amplitude from the EDB in response to distal stimulation as early as the first recording after surgery ($t = 7.2$) and at the second ($t = 7.0$). During the second elongation serial electrophysiological recordings showed a progressive recovery in mean C-MAP amplitude from the left EDB muscle, despite the fact that distraction of the left femur was still continuing. At the final recording, the mean value was not statistically different from the basal value. Simultaneously, on the right side, the mean amplitude of the C-MAP from the EDB showed a further significant decrease, which reached its peak ($t = 6.5$ as compared with the basal value) at the end of the second period. At the final recording, the mean amplitude had improved and was not

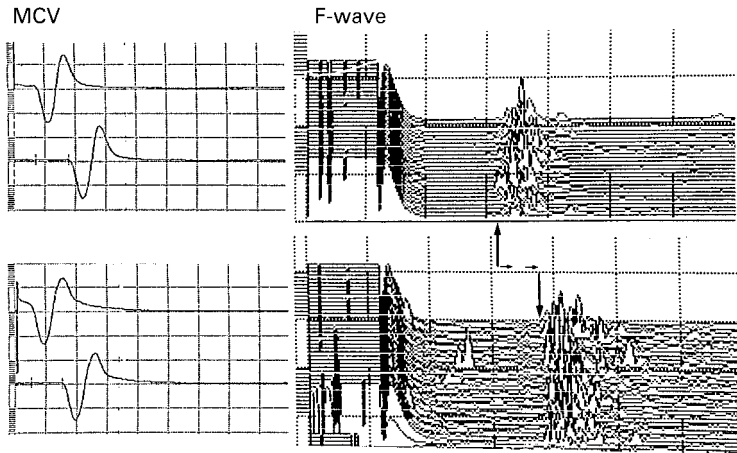


Fig. 3

Achondroplastic subject. Upper traces: MCV (on the left) and F-wave (on the right) from posterior tibial nerve under basal conditions. Lower traces: 16 months later after the end of bone lengthening. The MCV was unchanged, but the latency of the F-wave was prolonged (+9 ms, calculated on the rectified averaged mean, off line processing) (calibration: MCV: 5 ms/div, 5 mV/div; F-wave: 10 ms/div; 0.2 mV/div).

significantly different from the basal value ($t = 1.8$ for the left PN, $t = 2.2$ for the right PN).

Electrophysiological changes in response to stimulation of the posterior tibial nerve were similar to those to stimulation of the peroneal nerve although to a less extent and with no statistical significance ($t = 1.6$ for the left PTN, $t = 1.7$ for the right PTN).

The F-wave from stimulation of the peroneal nerve was not measured because the distal nerve damage precluded assessment of the more proximal portion.

The data on the F-wave resulting from stimulation of the posterior tibial nerve in basal conditions were compared with those obtained at the end of lengthening (Fig. 3). In AC subjects, the mean height increased from 121.6 ± 3.9 cm to 146.4 ± 4.6 cm and the mean latency of the F-wave changed from 31.0 ± 2.1 ms to 38.5 ± 3.6 ms ($r = 0.521$, $p = 0.08$). In SS subjects, the mean height increased from 153.8 ± 6.4 cm to 165.4 ± 6.8 cm and the mean latency of the F-wave from 42.8 ± 3.2 ms to 47.9 ± 3.8 ms (NS). In TS subjects, the mean height increased from 135.3 ± 2.5 cm to 151.5 ± 5.7 cm and the mean latency of the F-wave from 37.0 ± 3.2 ms to 45.9 ± 3.8 ms (NS).

The mean increase in limb length was greater in AC (24.8 cm = 52%) than in SS (11.6 cm = 16%) and in TS patients (16.2 cm = 26%). We calculated an index relating the delay in the mean latency of the F-wave (ΔF) to the increase in stature of the subjects (ΔH):

$$I = \Delta F / \Delta H \text{ (ms/cm)}$$

indicating that each cm of lengthening produced an F-wave delay of 0.30 ms in AC, 0.44 ms in SS and 0.56 ms in TS patients.

DISCUSSION

We have shown that limb lengthening by callotaxis may affect peripheral nerve function in patients with short stature of varying aetiology. Some degree of peroneal nerve palsy occurred in five patients (2 AC, 1 SS, 2 TS) always after tibial callotaxis, both during the first (three patients) and the second lengthening procedure (two patients). These

findings rule out the effect of the aetiology of the short stature on such peripheral nerve damage and suggest that the extent of the lengthening is not the main factor involved. They also indicate that the distraction of the femur is not a predisposing factor.

The C-MAP of the EDB muscle may be greatly reduced in amplitude both in proximal (just above the head of the fibula) and distal (just above the ankle) stimulation. Since this was seen at the first recording 10 to 12 weeks after surgery, it was due to axonotmesis; degenerating axons lost their excitability. Denervation potentials in needle EMG testing suggested that nerve dysfunction was caused by axonal damage. Since the denervation was found in muscles innervated by the common peroneal nerve, the site of the lesion must be close to the head of the fibula. We believe that the nerve damage may be due to surgical stress in this region and special care should be taken in this area during the operation.

Our results confirmed previous findings that measurement of the MCV is of little value in localising the lesion in contrast to evaluating both peroneal C-MAP and needle EMG.¹² Our serial long-term electrophysiological studies showed progressive recovery from severe axonal damage on the basis of change in amplitude of the motor action potentials. It is probable that with successful collateral or axonal reinnervation the amplitude will eventually increase since this does not directly reflect the number of surviving axons, but rather the functioning muscle mass.¹³

Our results agree with a previous report¹⁴ of electrophysiological signs of nerve damage during lower-limb lengthening, but differ in some respects and suggest that the lengthening may be regarded as causing minor injuries to the nerve trunks.

The true effect of bone distraction on nerves was more precisely revealed by F-wave analysis. Our data showed that the F-wave latency was longer in the final recording than under basal conditions in all patients. Since the MCV did not change significantly during bone distraction, the increase in the latency of the F-wave may be due to the slowing down of conduction along the more proximal part

of the nerve. From a pathophysiological point of view, the increase in the latency of the F-wave is consistent with the slowing of conduction. Small foci of myelin breakdown and abnormal remyelination could be caused by nerve stretching during limb lengthening. Such multifocal sites of damage are probably distributed along the whole length of the nerve as has been shown in experimental conditions.^{15,16} Achondroplastic patients had a higher resistance to stretching than other patients with other causes of short stature. The patients with Turner's syndrome showed the worse ratio between the amount of lengthening and the

increase in F-wave latency, and also had incomplete recovery of peroneal nerve palsy.

We conclude that the peroneal nerve may be damaged almost exclusively during the early phases of tibial callotaxis, probably as a result of direct mechanical stress. Despite continued bone distraction, there was good recovery in all but two subjects.

We wish to thank Mr D. Volpato for technical assistance during the electrophysiological recordings.

No benefits in any form have been received or will be received from a commercial party related directly or indirectly to the subject of this article.

REFERENCES

1. De Bastiani G, Aldegheri R, Renzi-Brivio L, Trivella G. Limb lengthening by callus distraction (callotaxis). *J Pediatr Orthop* 1987; 7:129-34.
2. Aldegheri R. Callotaxis. *J Pediatr Orthop* 1993;2,1:11-5.
3. Trivella G, Aldegheri R. Surgical correction of short stature. *Acta Paediatr Scand (suppl)* 1988;347:141-6.
4. Aldegheri R, Trivella G, Renzi-Brivio L, et al. Lengthening of the lower limbs in achondroplastic patients: a comparative study of four techniques. *J Bone Joint Surg [Br]* 1988;70-B:69-73.
5. Paley D. Problems, obstacles and complications of limb lengthening by the Ilizarov technique. *Clin Orthop* 1990;250:81-104.
6. Strong M. Circular fixation: Interviews with Prof. Dott Renato Spinelli. *Contemp Orthop* 1991;22:27-42.
7. Young NL, Davis RJ, Bell DF, Redmond DM. Electromyographic and nerve conduction changes after tibial lengthening by the Ilizarov method. *J Pediatr Orthop* 1993;13:473-7.
8. Fisher MA. H reflexes and F waves: physiology and clinical indications. *Muscle and Nerve* 1992;15:1223-33.
9. Manganotti P, Zanette G, Tinazzi M, Polo A. Dynamic F wave from lower limbs: value and clinical application. *Electromyogr Clin Neurophysiol* 1995;35:323-9.
10. Aldegheri R, Renzi-Brivio L, Agostini S. The callotaxis method of limb lengthening. *Clin Orthop* 1989;241:137-45.
11. Kimura J. *Electrodiagnosis in diseases of nerve and muscle: principles and practice*. Philadelphia: FA Davis Company, 1983.
12. Bashir Katirji M, Wilbourn AJ. Common peroneal mononeuropathy: a clinical and electrophysiologic study of 116 lesions. *Neurology* 1988;38:1723-8.
13. Falck B, Stålberg E. Motor nerve conduction studies: measurement principles and interpretation of findings. *J Clin Neurophysiol* 1995; 12:254-79.
14. Galardi G, Comi G, Lozza L, et al. Peripheral nerve damage during limb lengthening: neurophysiology in five cases of bilateral tibial lengthening. *J Bone Joint Surg [Br]* 1990;72-B:121-4.
15. Lee DY, Han TR, Choi IH, Lee CK, Chung SS. Changes in somatosensory-evoked potentials in limb lengthening: an experimental study on rabbits' tibiae. *Clin Orthop* 1992;285:273-9.
16. Strong M, Hruska J, Czynny J, et al. Nerve palsy during femoral lengthening: MRI, electrical and histologic findings in the central and peripheral nervous system: a canine model. *J Pediatr Orthop* 1994; 14: 347-51.