The importance of systematic histological examination after loosening of an implant

J. Allain, S. Le Mouel, M. C. Voiçin, G. Delepine, D. Goutallier

From Hôpital Henri Mondor, Creteil, France

A 65-year-old man presented with a painful hip five years after a cemented replacement. Histological examination of a biopsy taken from tissue surrounding the femoral implant showed infiltration of a squamous-cell carcinoma. Further investigation revealed a primary growth in the left lung. This rare example of a metastasis in relation to a joint replacement illustrates the necessity for histological examination of the tissue adjacent to a loose prosthesis.

J Bone Joint Surg [Br] 1998;80-B:591-4.
Received 19 December 1997; Accepted 3 February 1998

Some examples of primary malignant tumours associated with surgical implants have previously been described,[1-5] but the development of a metastasis in relation to a joint replacement is rare; only three cases have been reported hitherto.[6-8] We present a patient in whom a metastasis from a squamous-cell carcinoma developed in the periprosthetic neosynovial tissue five years after a cemented hip replacement, which had been undertaken for revision of a painful uncemented hemiarthroplasty.

Case report

A 78-year-old man, who was a heavy smoker, had pain in the left hip such that he could not walk more than one kilometre. He had experienced symptoms over the previous 13 years, and these had been managed by three injections of steroid into the joint. Radiographs showed degenerative changes in the hip secondary to congenital dysplasia, and in October 1987, an uncemented hemiarthroplasty had been performed in another centre. Recovery from the operation was satisfactory but the hip remained painful.

In December 1988, the patient returned with persistent pain in the hip. Radiological and haematological examination showed no evidence of sepsis. A cemented total hip arthroplasty was performed (Fig. 1a). Bacteriological and histological examination of the surrounding tissue showed no evidence of abnormality. He mobilised well after operation and the hip was free from pain for four years.

In August 1992, he began to complain of pain in the hip. The ESR was 60 mm/hour and the C-reactive protein level 53 mg (normal value <5 mg). He was given antibiotics by his general practitioner without improvement. In January 1993 a dental abscess was treated satisfactorily.

When seen in October 1993 he appeared well. There was a free range of movement in the hip but pain persisted, particularly on weight-bearing. On clinical examination small, tender mobile lymph glands were found in the left inguinal region. The ESR was 60 mm/hour and the C-reactive protein level 143 mg. Radiographs of the chest showed some widening of the mediastinum but the appearance of both lungs was normal. Those of the hip showed loosening of the femoral component which had drifted into varus and a radiolucent line was present between the cement of the cup and the acetabulum (Fig. 1b). Areas of endosteal lysis and cortical hypertrophy were present in the femur. It was thought that infection was present and the prosthesis was removed. At operation the bone appeared normal but the neosynovium and periprosthetic soft tissue were exuberant and inflamed. Gentamicin beads were placed in the residual space and the leg put on traction.

Culture of the specimens obtained during operation did not produce any growth although he had not received antibiotics in the previous six months. Histological examination of the periprosthetic neosynovial biopsy showed metastatic carcinomatous infiltration (Figs 2 and 3). The tissue showed oedema, interstitial infiltration of inflammatory polymorph cells and giant-cell granuloma around the cement holes. The superficial synoviocytes were hyperplastic with deposition of fibrin on the synovial surface. In the subintimal area the infiltrate was predominantly plasma cells largely infiltrated by lobules of immature squamous-cell carcinoma. The tumour was confined to the neosynovium. The six bone specimens analysed

J. Allain, MD, Chief Clinical Assistant
S. Le Mouel, MD, Consultant Orthopaedic Surgeon
G. Delepine, MD, Consultant Orthopaedic Surgeon
D. Goutallier, PhD, Professor of Orthopaedic Surgery
Service de Chirurgie Orthopédique
M. C. Voiçin, MD, Assistant Professor
Service d'Anatomie
Hôpital Henri Mondor, 51 Avenue du Marechal de Lattre de Tassigny, 94010 Creteil cedex, France.

Correspondence should be sent to Dr J. Allain.

©1998 British Editorial Society of Bone and Joint Surgery
0301-620X/98/48659 $2.00

Fig. 1a

Fig. 1b

Anteroposterior radiographs showing a) the hip after the primary arthroplasty and b) five years later with loosening of the femoral component. The large arrows indicate radiolucent lines between the implant and the cement laterally and between the cement and bone medially. The small arrows show the gap between the cement and bone in the acetabulum.

Fig. 2

Photomicrograph of the periprosthetic neosynovial biopsy showing infiltration by metastatic squamous-cell carcinoma (haematoxylin and eosin ×13).

showed no evidence of metastases. A radiograph of the chest showed atelectasis, widening of the mediastinum and an opacity in the upper part of the left lung. CT showed many mediastinal lymph nodes and a tumour in the left lung with hepatic metastases. A biopsy of a cervical node was performed ten days after the operation on the hip and histological examination revealed carcinoma cells.

Due to the short expectation of life, a total hip arthroplasty was carried out immediately after the histological diagnosis. The patient died three months later from disseminated metastatic disease and had a painless hip during that time.

Discussion

Metastatic spread to a joint replacement is exceptional. Only one case of non-Hodgkin's lymphoma,[6] one of bronchogenic carcinoma[7] and one of gastric carcinoma[8] have previously been described as metastasising to a prosthetic joint, into periprosthetic bone in the first two cases and the synovial tissue in the third. Several cases of malignancy have been reported associated with joint replacement or fracture fixation,[1-5] but no direct relationship has been demonstrated between implanted metal and adjacent sarcoma in patients.[5] The most common frequent histological

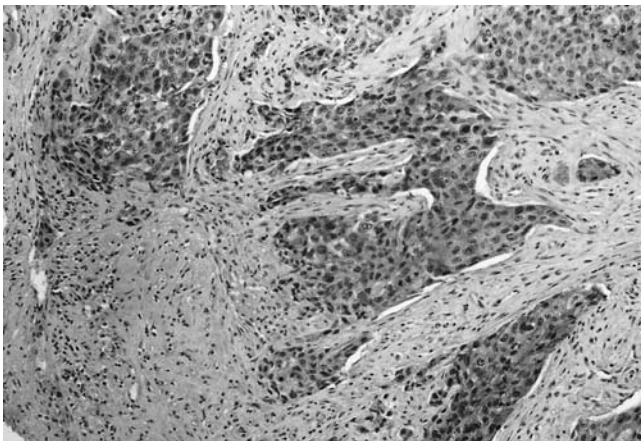

Fig. 3a

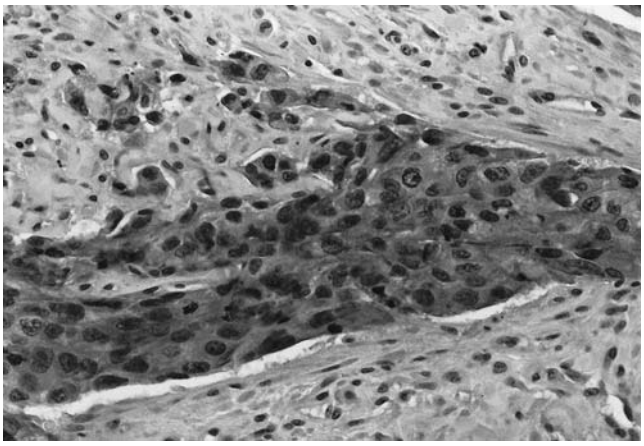

Fig. 3b

Photomicrographs of the periprosthetic biopsy showing the immunohistochemistry of the neosynovial tumour and immunoreactive keratin carcinomatous infiltration: a) antikeratin, APAP ×55; b) antikeratin, APAP ×140.

diagnosis is a malignant fibrous histiocytoma;[4,5] tumours reported include undifferentiated sarcoma,[3] squamous-cell carcinoma[2] and synovial sarcoma.[1]

Synovial metastasis after haematogenous dissemination of tumours is equally uncommon in normal joints, with eight cases (five women and three men) reported in the literature.[9] The primary diagnoses have always been wrong and have included septic arthritis, tuberculosis, rheumatoid arthritis and gout. Aspiration of the joint was carried out in five patients and in three the diagnosis was made from the synovial fluid which always contained red blood. Open biopsy was then undertaken to confirm the diagnosis.[9] The scarcity of synovial metastases may be explained by the large concentration of immune cells in the synovial tissue which helps to control metastatic seeding and the high rate of flow of the intrasynovial blood circulation.[10]

Roques et al[9] have suggested that abnormality of the blood flow secondary to injury may promote the development of metastases. Enneking[11] reported that metastatic lesions have a predilection for bones which have an abnormal increase in their blood supply. Biological changes have been described around metal and cement implants.[12] After operation the area of tissue damage and haematoma may be a suitable breeding ground for malignant cells circulating in the blood.[8,13] Kim and Yun[7] considered this mechanism to be the probable cause of one case of metastasis to a hip implant from a carcinoma of the lung which they had described. Kim and Yun[7] and Springfield[14] have suggested that the fibrin-platelet clots in the haematoma after surgery can foster the growth of metastatic tumour cells by chemical and mechanical effects. The platelet-derived growth factor may have an important role.[2]

Even if no metastatic cells have reached the periprosthetic bone, an inflammatory reaction in the bone to metastatic tumour, which would include macrophages, giant cells and leucocytes associated with necrosis of the bone tissue, is a possible cause of aseptic loosening of an implant. Even in the absence of tumour cells, metastatic loosening must be considered in the presence of haemarthritis. A synovial biopsy must be taken to confirm the diagnosis and, if the prosthesis is removed, histological analysis of the bone and synovium undertaken.

The cases of a primary malignancy associated with joint replacement reported in the literature have usually been thought initially to be of infection leading to loosening[4,6] unless there has been marked osteolysis or clear evidence of a tumour,[1,5] and only the histological examination has revealed the correct diagnosis. Feldman et al[15] recommend analysis of frozen sections of periprosthetic tissue in the presence of loosening. Histological examination of the material found at operation must always be carried out particularly when sepsis has been suspected but no growth obtained. Once the presence of malignancy has been confirmed a total hip arthroplasty must be performed in order to allow the patient to have a painless joint for the short time for which they are likely to survive.[1-3,7,8]

There is no direct evidence to link the material of a joint arthroplasty with neoplasia, and metastasis of a primary growth to tissue adjacent to prostheses is a rare cause of loosening. It is necessary, however, to be aware of this and to subject tissue from the side of loosening to histological examination so that the correct diagnosis is made.

No benefits in any form have been received or will be received from a commercial party related directly or indirectly to the subject of this article.

References

1. **Lamovec J, Zidar A, Čuček-Pleničar M.** Synovial sarcoma associated with total hip replacement: a case report. *J Bone Joint Surg [Am]* 1988;70-A:1558-60.
2. **Mazabraud A, Florent J, Laurent M.** A case of epidermoid carcinoma developing from contact with an articular hip prosthesis. *Bull Cancer (Paris)* 1989;76:573-81.
3. **Ryu RKN, Bovill EG Jr, Skinner HB, Murray WR.** Soft tissue sarcoma associated with aluminum oxide ceramic total hip replacement: a case report. *Clin Orthop* 1987;216:207-12.
4. **Troop JK, Mallory TH, Fisher DA, Vaughn BK.** Malignant fibrous histiocytoma after total hip arthroplasty: a case report. *Clin Orthop* 1990;253:297-300.

5. **Jacobs JJ, Rosenbaum DH, Hay RM, Gitelis S, Black J.** Early sarcomatous degeneration near a cementless hip replacement: a case report and review. *J Bone Joint Surg [Br]* 1992;74-B:740-4.

6. **Donohoe KJ, Patton DD.** Metastatic non-Hodgkin's lymphoma on bone scintigraphy mimicking loosening or infection of hip prosthesis. *Clin Nucl Med* 1987;12:888-9.

7. **Kim YH, Yun YH.** Metastasis of lung carcinoma to proximal femur after hip implant. *Orthop Rev* 1986;15:534-9.

8. **Kolstad K, Högstorp H.** Gastric carcinoma metastasis to a knee with a newly inserted prosthesis: a case report. *Acta Orthop Scand* 1990; 61:369-70.

9. **Roques C-F, Amigues H, Puget J, et al.** Métatase synoviale du genou, premier symptôme d'un cancer de l'estomac. *Rev Med* 1974; 10:235-9.

10. **Schumacher HR Jr.** The microvasculature of the synovial membrane of the monkey: ultrastructural studies. *Arthritis Rheum* 1969;12:387-404.

11. **Enneking WF.** *Musculoskeletal tumor surgery.* Vol. 1. New York: Churchill Livingstone, 1983.

12. **Charnley J.** The reaction of bone to self-curing acrylic cement: a long-term histological study in man. *J Bone Joint Surg [Br]* 1970; 52-B:340-53.

13. **Murthy SM, Goldschmidt RA, Rao LN, et al.** The influence of surgical trauma on experimental metastasis. *Cancer* 1989;64: 2035-44.

14. **Springfield DS.** Mechanisms of metastasis. *Clin Orthop* 1982;169: 15-9.

15. **Feldman DS, Lonner JS, Desai P, Zuckerman JD.** The role of intraoperative frozen sections in revision total joint arthroplasty. *J Bone Joint Surg [Am]* 1995;77-A:1807-13.