

# Extensor carpi radialis brevis

## AN ANATOMICAL ANALYSIS OF ITS ORIGIN

B. Greenbaum, J. Itamura, C. T. Vangsness, J. Tibone, R. Atkinson

From the University of Southern California School of Medicine, Los Angeles, USA

**We studied the origin of extensor carpi radialis brevis using 40 fresh frozen human cadaver specimens. Ten were stained with haematoxylin and eosin and trichrome which showed the collagenous structure of the extensor tendons at their origin. Gross anatomical observation showed that there was no definitive separation between brevis and communis at the osseotendinous junction. The histological findings confirmed the lack of separation between the two tendons. The extensor tendons were in close proximity to the joint capsule but trichrome staining showed no interdigitation of the tendon with the capsule. The validity of ascribing the pain of lateral epicondylitis to extensor carpi radialis brevis must be questioned. It appears to arise more from the 'common extensor' origin.**

*J Bone Joint Surg [Br] 1999;81-B:926-9.*

*Received 19 October 1998; Accepted after revision 8 January 1999*

Lateral epicondylitis, or 'tennis elbow' as it is more commonly known, denotes pain along the lateral aspect of the elbow typically exacerbated by extension of the wrist. While most authors agree that the aetiology is related to overuse,<sup>1</sup> the precise nature of the abnormality is uncertain. Based on physical or intraoperative examination most authors place the pathology at the origin of extensor carpi radialis brevis,<sup>1-6</sup> but isolating the origin of this muscle is very difficult. Our aim was to describe the gross and microscopic anatomy of the origin of extensor carpi radialis

brevis and its relationship to the surrounding muscles and elbow capsule, and to determine the site of the pain of lateral epicondylitis.

### Material and Methods

We obtained 40 fresh frozen specimens of human elbows. These were thawed to room temperature and the skin and subcutaneous tissues carefully removed. We did not know the age, gender or previous clinical details of the specimens. The antebrachial fascia was excised and the individual extensor muscles isolated. They were then dissected proximally towards their common origin on the lateral condyle. Specific attention was given to the relationship of the origin of extensor carpi radialis brevis to the surrounding muscles and elbow. All the specimens were photographed and illustrated (Fig. 1).

For histological evaluation, the origins of extensor carpi radialis longus and brevis, extensor digitorum communis and carpi ulnaris were isolated by sharp dissection as a unit from their osseous origin.

Each specimen was marked for orientation, fixed in 10% buffered formalin for 24 hours, dehydrated in graded alcohols, clarified in xylene and embedded in paraffin. Sagittal sections 3 µm thick were stained with haematoxylin and eosin, mounted on glass slides and examined by light microscopy. To determine the localisation of collagen one-third of the specimens was stained using Masson's trichrome technique.

### Results

**Gross anatomy.** Gross anatomical dissection of the elbows confirmed the difficulty in isolating the origin of extensor carpi radialis brevis. To visualise adequately the tendinous origin of the muscle, the dissection was started 5 cm distally at the level of the musculotendinous junction and taken proximally. In ten of the 40 specimens (25%) the tendon of brevis was seen to run under the muscle belly of longus and communis such that its origin on the condyle was not identifiable. The remaining 30 specimens showed that the smaller tendon of brevis interdigitated with that of communis at its origin forming a large aponeurosis (Fig. 2). The centre of this coalescence was found

B. Greenbaum, MD  
University of Southern California/County General Hospital, Room 3900,  
Los Angeles, California 90033, USA.

J. Itamura, MD, Assistant Professor  
C. T. Vangsness, MD, Associate Professor  
J. Tibone, MD, Clinical Professor  
Department of Orthopaedics  
R. Atkinson, MD, Assistant Professor  
Department of Pathology  
University of Southern California, 1510 San Pablo, Los Angeles, California 9003, USA.

Correspondence should be sent to Dr B. Greenbaum.

©1999 British Editorial Society of Bone and Joint Surgery  
0301-620X/99/59566 \$2.00

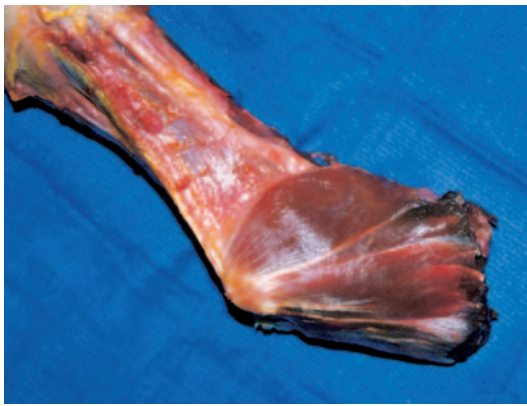


Fig. 1a

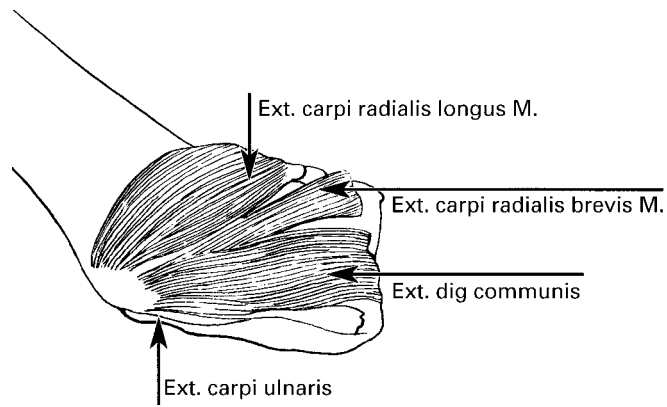


Fig. 1b

Photograph (a) and diagram (b) of a right elbow. The anatomy of the muscles of the lateral elbow is seen.

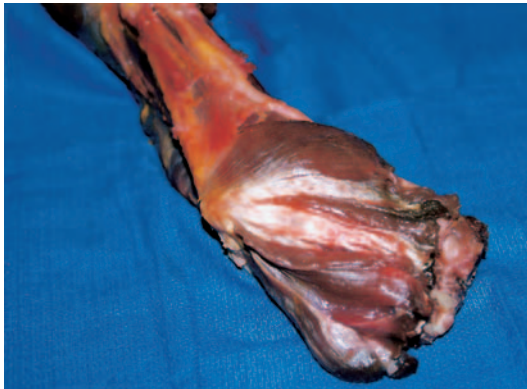

Fig. 2a

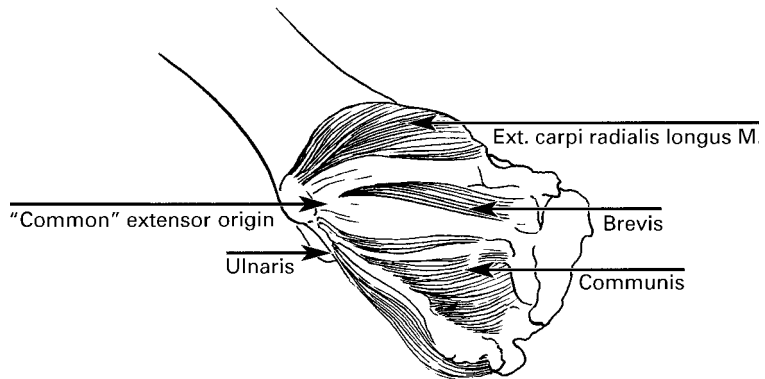


Fig. 2b

Photograph (a) and diagram (b) of the deeper right elbow. The muscle bellies of extensor brevis and communis are reflected inferiorly off their fascia. The two muscles converge at the lateral epicondyle to form one large aponeurosis. Extensor longus and carpi ulnaris have distinctly separate origins from extensor brevis and communis.

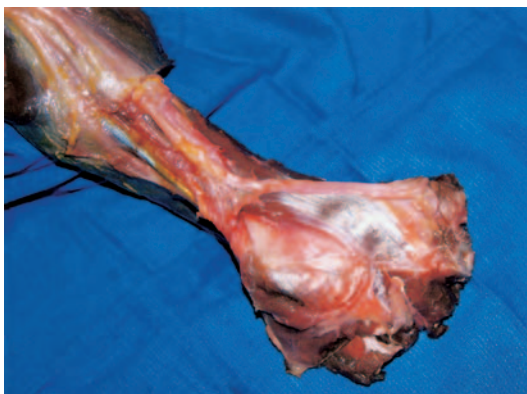


Fig. 3a

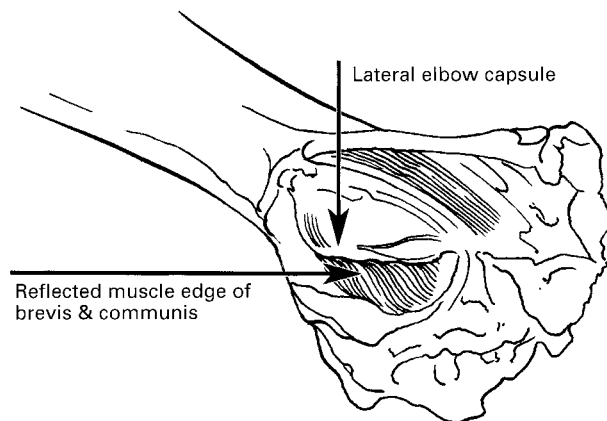


Fig. 3b

Photograph (a) and diagram (b) of extensor brevis and communis reflected inferiorly off the lateral epicondyle. There is a clear separation of the two tendons away from the joint capsule of the lateral elbow. The capsule lies directly medially and inferiorly to this common extensor mass.

consistently over the most prominent and lateral portion of the condyle. A portion of the brevis tendon was noted to attach more anteriorly with its fibres more axially orientated, while a portion of the communis tendon was attached more inferiorly with a sagittal orientation. In all

dissections there was a lack of a definitive separation of brevis and communis at the osseotendinous junction. The origins of extensor carpi radialis longus and extensor carpi ulnaris were noted to be separate from the 'common extensor' origin (Fig. 2). Tears of the tendon or bony

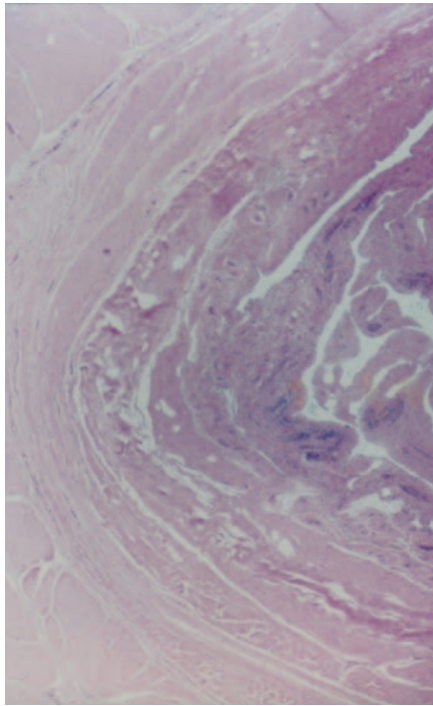


Fig. 4a

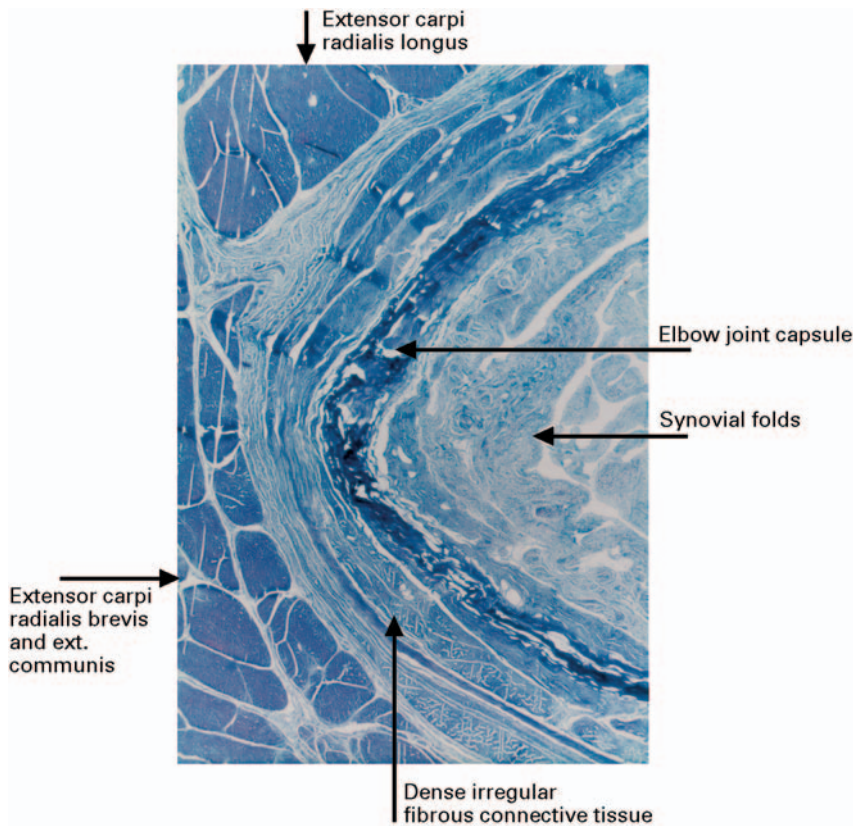


Fig. 4b

Photomicrographs showing that extensor carpi radialis longus is separated from extensor brevis and communis by dense irregular connective tissue ((a) haematoxylin and eosin, (b) Masson trichrome  $\times 30$ ).

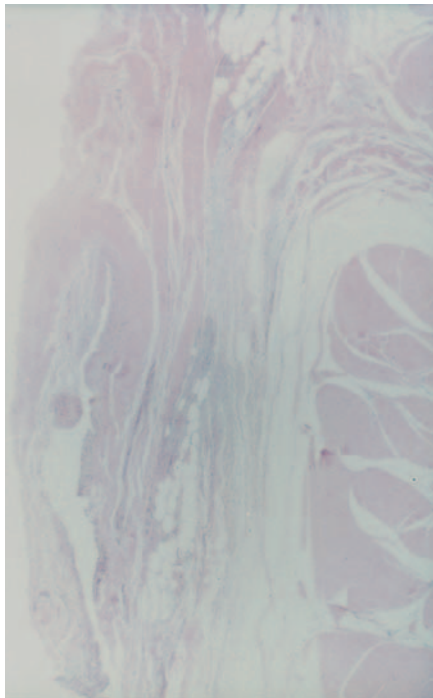


Fig. 5a

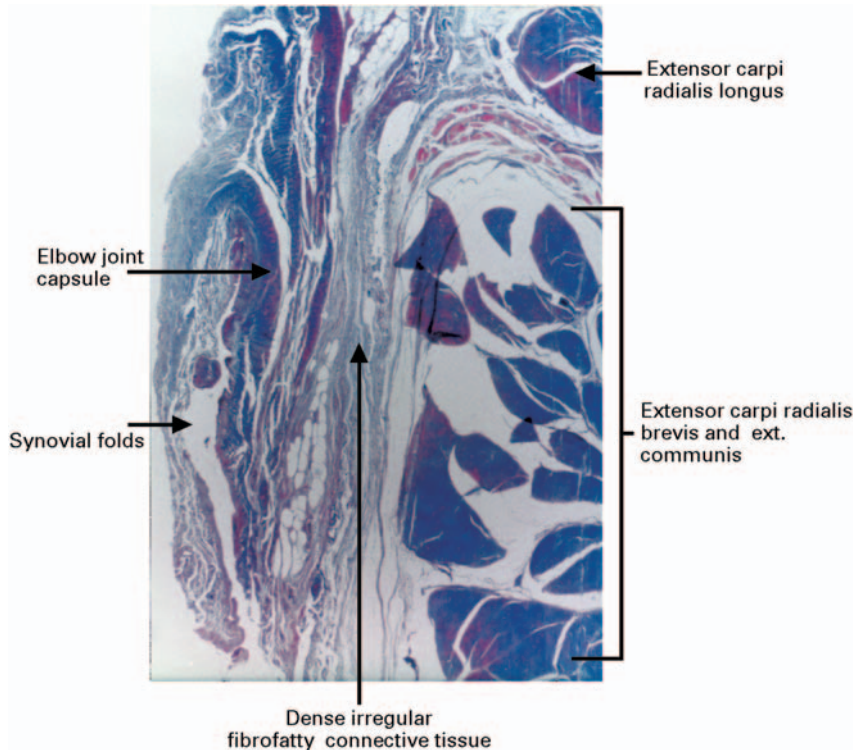


Fig. 5b

Photomicrographs showing that the joint capsule of the lateral elbow and the common extensors are separated by a layer of dense fibrofatty irregular connective tissue ((a) haematoxylin and eosin, (b) Masson trichrome  $\times 30$ ).

abnormality were not found in any of the specimens. The joint capsule and lateral collateral ligament were located medially and inferiorly to the centre of the common extensor mass. While these structures were found to be close, they did not coalesce (Fig. 3).

**Microscopic anatomy.** Microscopic examination of the specimens confirmed the findings of the gross dissections. The tendons of extensor brevis and communis were indistinguishable at the osseotendinous origin and appeared to be interdigitated. On two of the specimens the tendinous structures were divided by an extremely thin band of fat and loose connective tissue. Histologically, neither of the tendons of brevis or communis could be identified. Trichrome staining showed that they did not separate into two structures at the lateral epicondyle (Fig. 4). The origins of extensor carpi radialis longus and extensor carpi ulnaris were separated from the 'common extensor' origin by loose connective tissue and fat. The joint capsule was noted to be close to the aponeurotic structure but was separated by a layer of dense fibrofatty tissue (Fig. 5).

## Discussion

Lateral epicondylitis or 'tennis elbow' is a common problem typically affecting patients in their fourth decade. Its most characteristic findings are pain and tenderness over the lateral epicondyle. Over the past 100 years, since its first description, there have been many theories regarding its aetiology which have included bursitis, periostitis, infection, aseptic necrosis, and neuritis.<sup>4,6</sup> The most widely accepted suggests the presence of macro- or microtears in the tendon of extensor carpi radialis brevis, based on findings extrapolated from abnormal physical and intra-operative examinations showing 'gross alterations in the (brevis) tendon'.<sup>1,3,4,6</sup> Treatment of this problem is difficult and controversial.<sup>7</sup>

During the course of our gross and microscopic dissections it was clear that even under the most controlled

situation, as in a cadaver dissection, it was not possible to separate the origin of brevis from the common extensor tendon. At times, the tendons appeared to interdigitate. Furthermore, it was noted that the most accurate way to trace the origin of brevis was by dissecting from distal to proximal. This wide exposure had not been performed in previous reports since incisions were created at the origin of the muscle.<sup>1</sup> Previous work done by Goldie<sup>6</sup> may be inaccurate because he 'did not use a tourniquet' and therefore was not able to see the extent of the pathology. Even with a tourniquet, visualisation of this area is not precise. We found the 'common extensor' origin to be a separate structure from that of extensor carpi radialis longus and extensor carpi ulnaris.

The relationship of the tendons of brevis and extensor communis was so intimate that pathology believed to be isolated to brevis must be common to both. Our gross and histological dissections have failed to give well-delineated anatomical reasons for ascribing the pain of lateral epicondylitis to extensor carpi radialis brevis. At this site the muscle forms one common tendon with that of extensor digitorum communis.

No benefits in any form have been received or will be received from a commercial party related directly or indirectly to the subject of this article.

## References

1. Nirschl RP, Pettrone FA. Tennis elbow. *J Bone Joint Surg [Am]* 1979;61-A:832-9.
2. Boyd HB, McLeod AC. Tennis elbow. *J Bone Joint Surg [Am]* 1973; 55-A:1183-7.
3. Coonrad RW, Hooper WR. Tennis elbow: its course, natural history, conservative and surgical management. *J Bone Joint Surg [Am]* 1973; 55-A:1177-82.
4. Cyriax JH. The pathology and treatment of tennis elbow. *J Bone Joint Surg* 1936;18:921-40.
5. Garden RS. Tennis elbow. *J Bone Joint Surg [Br]* 1961;43-B:100-6.
6. Goldie I. Epicondylitis lateralis humeri (epicondylalgia or tennis elbow): a pathogenetical study. *Acta Chir Scand Suppl* 1964:339.
7. Labelle H, Guibert R, Joncas J, et al. Lack of scientific evidence for the treatment of lateral epicondylitis of the elbow: an attempted meta-analysis. *J Bone Joint Surg [Br]* 1992;74-B:646-51.