Periacetabular osteotomy in the treatment of neurogenic acetabular dysplasia

S. J. MacDonald, O. Hersche, R. Ganz

From the London Health Sciences Centre, London, Canada

We carried out the Bernese periacetabular osteotomy for the treatment of 13 dysplastic hips in 11 skeletally mature patients with an underlying neurological diagnosis. Seven hips had flaccid paralysis and six were spastic. The mean age at the time of surgery was 23 years and the mean length of follow-up was 6.4 years. Preoperatively, 11 hips had pain and two had progressive subluxation.

Before operation the mean Tönnis angle was 33°, the mean centre-edge angle was -10°, and the mean extrusion index was 53%. Postoperatively, they were 8°, 25° and 15%, respectively. Pain was eliminated in 7 patients and reduced in four in those who had preoperative pain. One patient developed pain secondary to anterior impingement from excessive retroversion of the acetabulum. Four required a varus proximal femoral osteotomy at the time of the pelvic procedure and one a late varus proximal femoral osteotomy for progressive subluxation.

Before operation no patient had arthritis. At the most recent follow-up one had early arthritis of the hip (Tönnis grade I) and one had advanced arthritis (Tönnis grade III).

Our results suggest that the Bernese periacetabular osteotomy can be used successfully to treat neurogenic acetabular dysplasia in skeletally mature patients.

J Bone Joint Surg [Br] 1999;81-B:975-8.
Received 2 December 1998; Accepted after revision 21 April 1999

S. J. MacDonald, MD, FRCS C, Assistant Professor
Department of Orthopaedic Surgery, London Health Sciences Centre, University Campus, 339 Windermere Road, London, Ontario, Canada N6A 5A5.

O. Hersche, MD, Assistant Professor
Sonnenhof, Buchserstrasse 30, 3006 Berne, Switzerland.

R. Ganz, MD, Professor and Chairman
Department of Orthopaedic Surgery, University of Berne, 3010 Berne, Switzerland.

Correspondence should be sent to Dr S. J. MacDonald.

©1999 British Editorial Society of Bone and Joint Surgery
0301-620X/99/69700 $2.00

There have been many studies on the management of the dislocated or subluxed hip in children with an underlying neurological disorder,[1-4] but there are few reports on the spastic or flaccid paralytic dysplastic hip in the adolescent or young adult.

Acetabular dysplasia, as a sequel to underlying spasticity, has been well documented.[5] Muscle imbalance and bony deformity subsequently lead to progressive subluxation and dislocation of the hip. The incidence is from 2% to 60%. Howard et al[6] reported an incidence of instability of the hip of 59% among 44 patients with spastic quadriplegia. Patients with diplegia and hemiplegia are much less likely to develop instability. The natural history of the dislocated hip in spasticity has been studied by Moreau et al[7] who found instability in 41 (47%) of 88 patients and noted that half of the dislocated hips were painful. Bagg et al[1] noted that in their patients 8 of 9 dislocated hips, and 11 of 24 of those subluxated, were painful.

Since 1984, we have treated skeletally mature patients with acetabular dysplasia, secondary to an underlying neurological disorder, by the Bernese periacetabular osteotomy.[8] We now present our results.

Patients and Methods

We included all patients with acetabular dysplasia and an underlying neurological disorder who had been treated by a periacetabular osteotomy and had a minimum follow-up of three-years. Between 1984 and 1995 we had performed this procedure on 13 dysplastic hips (11 patients). There were six women and five men with a mean age at the time of operation of 23 years (13 to 50). All were skeletally mature.

There were two distinct groups based on the underlying neurological process. Six hips were spastic, five secondary to cerebral palsy and one due to arthrogryposis, and seven were flaccid, four secondary to poliomyelitis, one because of spina bifida and two after resection of medulloblastomas. The indication for surgery was progressive pain in 11 of the 13 hips and progressive subluxation in the other two.

The technique of the Bernese periacetabular osteotomy was first described in 1988[8] and has evolved with minor changes.[9] We used a modified Smith-Petersen approach to the hip, protecting the lateral femoral cutaneous nerve in two ways. First, the fascia over the tensor fascia lata was

Fig. 1a

Fig. 1b

Fig. 1c

Fig. 1d

Radiographs of a 29-year-old man who had poliomyelitis at four years of age showing a) an AP view of the pelvis with severe acetabular dysplasia and subluxation of the femoral head), b) a 'false-profile view' with severe dysplasia and deficient coverage of the head, c) an AP view of the pelvis seven years after periacetabular osteotomy showing marked improvement from the preoperative state, although the patient still had some pain and d) a 'false-profile' view at seven years, with improvement in the coverage of the femoral head.

incised laterally, and secondly, an osteotomy of the anterior superior iliac spine with the sartorius and inguinal ligament attached, was carried out to reduce the tension on the nerve during retraction. At first, the origins of the tensor fascia lata and gluteus medius and minimus were stripped, but our experience and that of others[10] have shown this to be unnecessary for an adequate exposure. It also prevents the complication of clinically significant heterotopic ossification. Both heads of the rectus femoris were detached from their origins and reflected medially. Fibres of the iliacus muscle which insert on the anterior capsule were dissected until the psoas tendon was exposed. The plane of dissection continued towards the ischium. The medial femoral circumflex artery was not compromised provided that dissection was not distal to the obturator externus muscle. The ischium was palpated but not seen. The ischium, pubis and ilium were osteotomised. The posterior column of the pelvis was kept intact and the osteotomised acetabular fragment was completely free from attachment to the surrounding bone in order to rotate it laterally, anteriorly and medially as necessary to achieve optimal coverage. Intraoperative radiographs were obtained to ensure proper

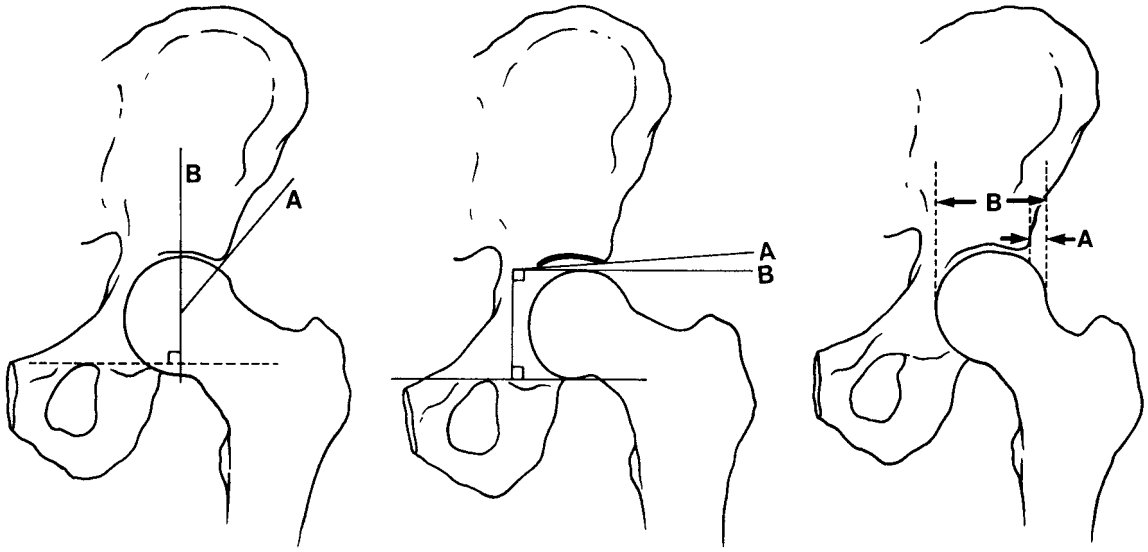

Fig. 2 Fig. 3 Fig. 4

Figure 2 – The centre-edge angle of Wiberg is formed between two lines passing through the centre of the femoral head one of which extends to the lateral edge of the sourcil (A) and the other is a perpendicular to the interteardrop line (B). The normal angle in an adult is greater than 25°. Figure 3 – The acetabular index angle of the weight-bearing zone as described by Tönnis is the angle between a line parallel to the acetabular sourcil (A) and a line parallel to the interteardrop line (B). The normal angle in an adult is 10 ± 2°. Figure 4 – The extrusion index of the femoral head is determined by measuring in millimetres the amount of the lateral part of the femoral head which is not contained by the acetabulum (A) and dividing this by the total width of the head (B). Therefore A/B × 100 gives the percentage which is extruded or uncovered.

placement. It was then fixed with three 3.5 mm fully-threaded cortical screws. Congruence and containment of the femoral head were assessed on the radiograph. If there was residual subluxation of the femoral head or incongruence, despite appropriate acetabular positioning, an abduction radiograph was obtained. If congruence or containment was then improved, a proximal femoral varus osteotomy was undertaken. If necessary, derotation or extension was carried out to correct deformities.

The mean length of follow-up was 6.4 years (3.5 to 12). All patients were assessed clinically and radiologically at their most recent review. Anteroposterior (AP), lateral and false-profile[11] radiographs were evaluated before and after operation and at the last follow-up (Fig. 1). The only film which all the patients had available for review from each visit was the AP view and this radiograph was used for the study. The measurements included the centre-edge angle of Wiberg[12] (Fig. 2), the acetabular index angle of Tönnis[13] (Fig. 3) and the extrusion index[14] (Fig. 4). Each radiograph was assessed for the presence of arthritis which was classified according to Tönnis[13] as follows: grade 1, sclerosis of the femoral head and acetabulum, with only a mild decrease in the joint space; grade 2, small cysts in the head or acetabulum, with a moderate decrease in the joint space; and grade 3, formation of large cysts with moderate to complete loss of the joint space and possible collapse of the head.

Results

All patients were followed postoperatively by serial radiography to assess specific measurements. The mean centre-edge angle of Wiberg was -10° (-38 to +8) before and 25° (5 to 45) after operation. At the most recent review this angle had not changed, with a mean of 26° (0 to 48).

The mean Tönnis angle was 33° (15 to 60) before and 7.7° (-4 to +33) after operation. At the latest follow-up it was 9.9° (-8 to +34).

The mean extrusion index was 53% (19 to 79) before and 15% (-1 to 45) after operation, and was 18% (-1 to 48) at the latest review.

There were two distinct subgroups of patients based on their underlying neurological disorder. Dysplastic patients who had a flaccid paralytic hip had more preoperative subluxation than in those with spasticity, as demonstrated by the mean preoperative Wiberg angle (-19.3 *v* 0.8) and their increased preoperative extrusion index (66 *v* 38). The

Table I. The correction achieved in the six spastic and seven flaccid hips as measured by specific radiological parameters

	Spastic			Flaccid		
	Preop	**Postop**	**Long-term**	**Preop**	**Postop**	**Long-term**
Wiberg angle (degrees)	0.8	29.2	31.0	-19.3	22.1	21.9
Tönnis angle (degrees)	26.5	4.2	4.5	39.0	10.7	14.6
Extrusion index (%)	*38.0*	*9.0*	*13.0*	*66.0*	*21.0*	*23.0*

flaccid group also had more severe dysplasia with a more vertical preoperative Tönnis angle (39.0 *v* 26.5). Good correction was achieved in both groups, but the flaccid group had slightly less (Table I).

All patients had a standard Bernese periacetabular osteotomy. No additional soft-tissue procedures were carried out. Three of the four patients who had a varus proximal femoral osteotomy at the time of the acetabular procedure, had underlying spasticity. One patient required a varus proximal femoral osteotomy later for progressive lateral subluxation.

No patient had preoperative evidence of arthritis of the hip. At follow-up, two had developed arthritis, one of Tönnis grade I and the other of grade III. One patient, early in the series, developed anterior groin pain from impingement because the acetabulum had been placed in an excessively retroverted position.

Discussion

Untreated congenital dysplasia of the hip has a high incidence of late arthritis, approaching between 25% and 50% by the age of 30 years.[15,16] Our approach has been to redirect the acetabulum, using the Bernese periacetabular operation to cover and contain the femoral head. This operation has many advantages over previously described techniques. Large degrees of correction can be achieved which improve anterior and lateral coverage. The joint can be displaced medially. The posterior column of the pelvis is not divided, which allows early mobilisation of the patient after operation. The vascularity of the acetabular fragment is preserved and capsulotomy can be carried out to address intra-articular pathology without risk.

Both flaccid and spastic acetabular dysplasia was successfully treated by the periacetabular osteotomy, resulting in stability and containment of the femoral head. Good correction was achieved in all patients. In a series of non-neurogenic acetabular dysplasias published previously[8], appropriate coverage and containment were achieved by the periacetabular osteotomy alone in most cases and a femoral osteotomy was required in only 16 of 75 hips. In the current series, femoral osteotomy was undertaken in four of the patients and was required in 50% of the spastic hips. Therefore, although correction can be achieved with the periacetabular osteotomy in neurogenic acetabular dysplasia, it is crucial to assess containment and joint stability intraoperatively and to be prepared to carry out a proximal femoral osteotomy.

No benefits in any form have been received or will be received from a commercial party related directly or indirectly to the subject of this article.

References

1. **Bagg MR, Farber J, Miller F.** Long-term follow-up of hip subluxation in cerebral palsy patients. *J Pediatr Orthop* 1993;13:32-6.
2. **Root L, Laplaza FJ, Brourman SN, Angel DH.** The severely unstable hip in cerebral palsy: treatment with open reduction, pelvic osteotomy and femoral osteotomy with shortening. *J Bone Joint Surg [Am]* 1995;77-A:703-12.
3. **Mubarak SJ, Valencia FG, Wenger DR.** One-stage correction of the spastic dislocated hip: use of pericapsular acetabuloplasty to improve coverage. *J Bone Joint Surg [Am]* 1992;74-A:1347-57.
4. **Brunner R, Baumann J.** Clinical benefit of reconstruction of dislocated or subluxated hip joints in patients with spastic cerebral palsy. *J Pediatr Orthop* 1994;14:290-4.
5. **Bleck EE.** The hip in cerebral palsy. *Orthop Clin North Am* 1980;11:79-104.
6. **Howard CB, McKibbin B, Williams LA, Mackie I.** Factors affecting the incidence of hip dislocation in cerebral palsy. *J Bone Joint Surg [Br]* 1985;67-B:530-2.
7. **Moreau M, Drummond DS, Rogala E, Ashworth A, Porter T.** Natural history of the dislocated hip in spastic cerebral palsy. *Dev Med Child Neurol* 1979;21:749-53.
8. **Ganz R, Klaue K, Winh TS, Mast JW.** A new periacetabular osteotomy for the treatment of hip dysplasia: technique and preliminary results. *Clin Orthop* 1988;232:26-36.
9. **McGrory BJ, Trousdale RT, Cabanela ME, Ganz R.** Bernese periacetabular osteotomy: surgical technique. *J Orthop Tech* 1993;1:179-91.
10. **Millis MB, Murphy SB, Poss R.** Osteotomies about the hip for the prevention and treatment of osteoarthrosis. *J Bone Joint Surg [Am]* 1995;77-A:626-47.
11. **Lequesne M, de Seze S.** Le faux profil du bassin: nouvelle incidence radiographique pour l'étude de la hanche. Son utilité dans les dysplasies et les differentes coxopathies. *Rev Rhum* 1961;28:643-52.
12. **Wiberg G.** Studies on dysplastic acetabula and congenital subluxation of the hip joint: with special reference to the complication of osteoarthritis. *Acta Chir Scand* 1939;83:Suppl. 58.
13. **Tönnis D.** *Congenital dysplasia and dislocation of the hip in children and adults.* Berlin, etc: Springer-Verlag, 1987.
14. **Heyman CH, Herndon CH.** Legg-Perthes disease: a method for the measurement of the roentgenographic result. *J Bone Joint Surg [Am]* 1950;32-A:767-8.
15. **Aronson J.** Osteoarthritis of the young adult hip: etiology and treatment. *Instructional Course Lectures, AAOS* 1986;36:119-28.
16. **Cooperman DR, Wallensten R, Stulberg SD.** Acetabular dysplasia in the adult. *Clin Orthop* 1983;175:79-85.