

## Stenosis of the cervical canal in craniodiaphyseal dysplasia

S. Naique, V. J. Laheri

From the Seth GS Medical College and the King Edward VII Memorial Hospital, Mumbai, India

**C**raniodiaphyseal dysplasia (CDD) is a rare sclerosing bone disorder, the severity of which depends on its phenotypic expression. Hyperostosis can cause progressive foraminal stenosis leading to palsy of cranial nerves, epilepsy and mental retardation. We report the only case of CDD in an adult, with stenosis of the cervical canal leading to quadriplegia as a late complication of hyperostosis, and describe the problems associated with its treatment. Although the syndrome is rare, its pathophysiological and therapeutic considerations may be applicable to the management of stenosis of the spinal canal in other hyperostotic bone disorders.

*J Bone Joint Surg [Br] 2001;83-B:328-31.  
Received 16 October 2000; Accepted 20 November 2000*

Craniodiaphyseal dysplasia (CDD) is a rare, inherited bone disorder characterised by severe skeletal sclerosis, generalised hyperostosis and progressive craniofacial deformity.<sup>1-5</sup> The syndrome has a varying phenotypic expression and severely affected individuals die at an early age.<sup>1,6</sup> Less than 20 cases have been described, the oldest patient being 27 years of age at the time of publication.<sup>1</sup> Although the syndrome and its early complications are well described, the delayed complications in adults are not all known. We describe stenosis of the cervical canal as a late complication of this rare syndrome, and highlight the difficulties in its treatment.

### Case report

A 47-year-old male farmer presented with gradual onset of weakness in all four limbs, and bladder and bowel incon-

tinence of six months' duration. Since birth, his parents had noticed progressive enlargement of his face. His siblings (two brothers) had a normal facial appearance and there was no family history of any such disorder. He had not sustained any fractures or been hospitalised for conditions such as epilepsy. He had a peculiar facial appearance with an unusually large head, and was of tall stature (198 cm) with a generally large body habitus. Specifically, the craniofacial abnormalities included severe paranasal and glabellar bossing, a flattened nasal bridge (giving a leonine appearance), hypertelorism (inner and outer canthal distances greater than the 95th percentile), true macrocrania, and a prominent forehead. He had abnormal dentition with small irregular teeth, many being carious. Bilateral palsy of the facial nerve of the lower motor-neurone type was noticed, and incomplete bilateral hearing loss. His visual acuity was normal but he had mild mental retardation. There was an upper motor-neurone type of quadriplegia, with power in all limbs of MRC grade III. There was severe spasticity, with all reflexes being brisk, bilateral ankle clonus and extensor plantar responses. Sensory examination revealed no abnormality. He had urinary retention with overflow.

His blood profile was normal with no alteration of the serum calcium or phosphorus levels. The level of alkaline phosphatase was raised at 312 IU/l (normal range 50 to 134 IU/l). Assays for vitamin-D metabolites, calcitonin, serum acid phosphatase and parathyroid hormone were within normal limits. There was no evidence of anaemia or extramedullary haematopoiesis. Pure-tone audiometric studies revealed bilateral partial hearing loss which was more pronounced in the left ear.

A radiological skeletal survey revealed severe sclerosis and hyperostosis of the entire skeletal system, including the axial skeleton (Fig. 1). The skull was intensely sclerotic and enlarged, with obliteration of the diploic spaces and the air sinuses (Fig. 2). The hyperostosis in the cervical spine was so far advanced that it caused severe circumferential stenosis of the spinal canal extending from C2 to C6 (Fig. 3). The spinal elements were also enlarged. The long bones were cylindrical in appearance and densely sclerotic. They showed endosteal, diaphyseal and cortical thickening, suggesting lack of modelling (Fig. 4). A CT scan and myelogram of the cervical spine confirmed extensive stenosis

S. Naique, MS Orth, FRCS, Trauma Fellow  
Department of Orthopaedics, Charing Cross Hospital, Fulham Palace Road, London W6 8RF, UK.

V. J. Laheri, MS Orth, Professor and Head  
Department of Orthopaedics, The Seth GS Medical College & The King Edward VII Memorial Hospital, Mumbai 400012, India.

Correspondence should be sent to Mr S. Naique.

©2001 British Editorial Society of Bone and Joint Surgery  
0301-620X/01/311795 \$2.00

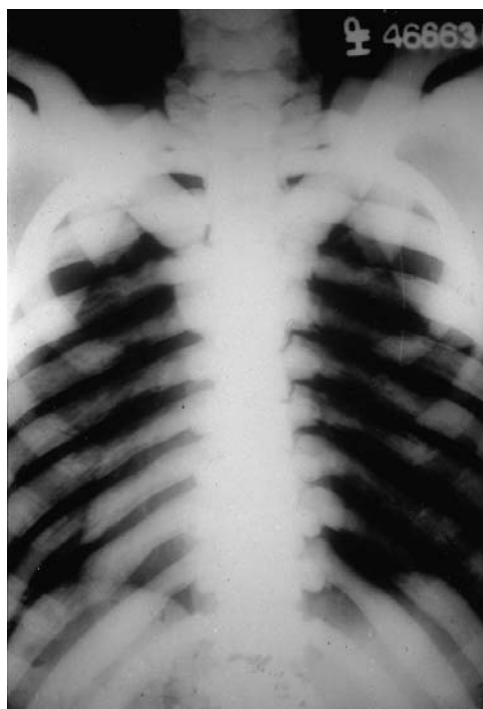


Fig. 1

AP radiograph of the chest showing uniform sclerosis, including the ribs, thoracic spine, clavicles and scapulae.

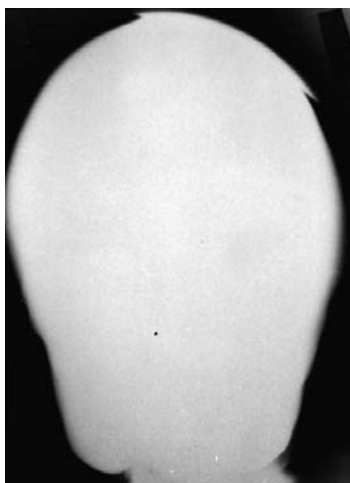


Fig. 2a

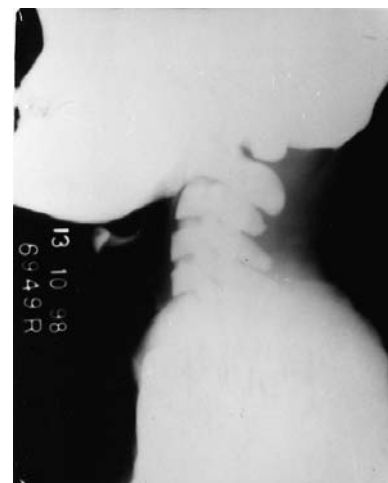

Fig. 2b

AP (a) and lateral (b) radiographs of the skull.

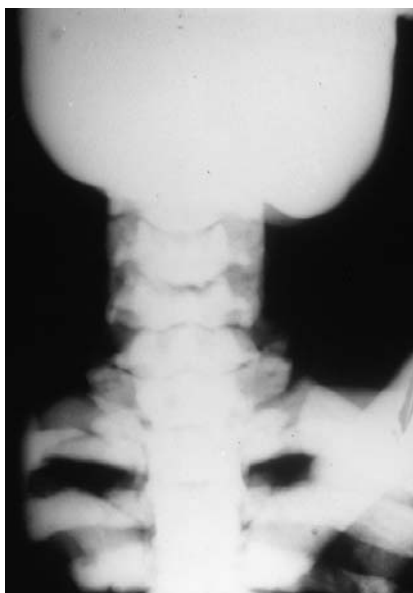

Fig. 3a

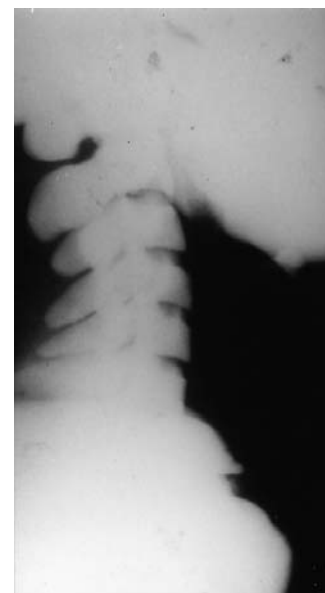

Fig. 3b

AP (a) and lateral (b) radiographs of the cervical spine showing the sclerotic and hyperostotic skull, vertebral elements and the severe stenosis of the spinal canal. Note the enlarged spinal elements.

from C2 to C6, with extradural compression of the cord (Fig. 5). There was free flow of the dye beyond the cervical canal. There was no evidence of localised cord compression, and no anomaly of the cord was noted.

In view of the severe symptomatology and the nature of the stenosis, a posterior decompression from C2 to C6 was planned. Endotracheal intubation proved difficult, but was achieved without the help of a fibre-optic endoscope. A specially designed headpiece was used which was much larger than normal because of the patient's large and heavy head. On exposure, the posterior elements were gigantic and ivory white in colour. The bone was extremely hard (but not brittle) and unyielding to any bone-cutting instrumentation. All attempts to remove the spinous processes

with nibblers (of various sizes), osteotomes, and a pneumatic burr (speed 9000 rev/min) failed. The surgery was abandoned. Postoperatively, the patient showed transient neurapraxia (myelopathy only) but recovered to his pre-operative neurological status within two days. After two weeks, his neck was re-explored. This time a very high-speed burr (speed 90 000 to 130 000 rev/min) was used and laminectomy was achieved from C2 to C6. The ligamentum flavum was normal in colour and texture, with no evidence of calcification. No facet hypertrophy was noted. The dura showed no adhesion to the ligamentum flavum and there was expansion and pulsation of the cord after decompression. Histopathological examination of the excised bone revealed an increase in the number and thickness of

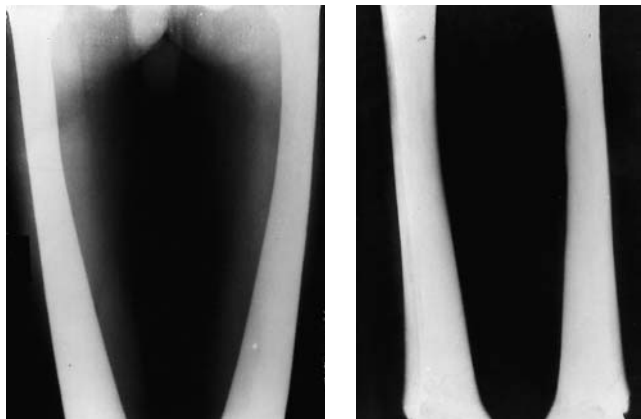


Fig. 4a

Fig. 4b

AP radiographs of both femora (a) and both tibiae (b) showing sclerosis and absence of the medullary canal with a remodelling defect.

the trabeculae. Postoperatively, he had increased weakness of his right arm with MRC grade-I power in the elbow and shoulder muscles. Otherwise, his neurological status was unchanged. Over a period of six weeks he showed progressive recovery of power in his limbs (except the right arm) to MRC grade IV and a significant decrease in spasticity. The flexor spasms abated, and he could sit up without support. The paresis of the right C5 and C6 roots recovered only to MRC grade III and remained at that level. He refused further investigation. He regained some bladder control and was comfortable with intermittent self-catheterisation, and he recovered full bowel control. At three months the spasticity was moderate and he could stand and walk slowly with aid. After one year he had

incomplete neurological recovery with residual spasticity and C5 and C6 root weakness on the right side, of MRC grade-III power.

## Discussion

CDD is the most severe of all forms of sclerotic bone disorder. Although first reported by Halliday,<sup>2</sup> Joseph et al<sup>3</sup> described the early features of the syndrome and named it progressive craniodiaphyseal dysplasia. Ghorlin, Spranger and Koszalka<sup>4</sup> described the syndrome in its entirety and identified previously published cases, which had been described as cases of leontiasis ossea. The genetics of the disorder remain unclear, although it has been suggested that it may be autosomal recessive in inheritance, with an incidence of only 0.1/million.<sup>1,2,4,7,8</sup>

Classically, CDD is characterised by generalised hyperostosis and sclerosis, particularly in the skull, mandible and facial bones, leading to severe deformity. Patients with CDD usually present in infancy with typical facies or complications such as respiratory obstruction caused by choanal stenosis.<sup>1</sup> Relentless deposition of bone leads to progressive stenosis of the craniofacial foramina. Neurological complications which have been described include mental retardation and epilepsy (due to cranial encroachment) and palsy of the cranial nerves (II, VII and VIII) caused by foraminal stenosis.<sup>1-5,9,10</sup> There is no detailed description, however, of similar phenomena occurring in the spine leading to quadriparesis. There may be deafness, which is due to a combination of stenosis of the internal auditory meatus, narrowing of the cavity of the middle ear, and compression of the VIIth and VIIIth cranial nerves.<sup>9-12</sup>

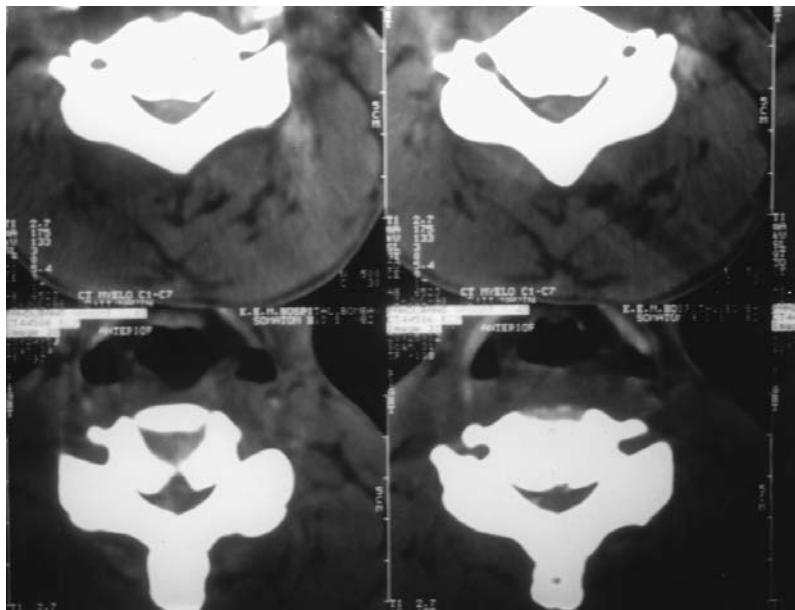


Fig. 5

CT scan of the cervical spine showing the circumferential stenotic spinal canal. Note the cord, as delineated by the myelographic dye. There is no evidence of osteophytes or localised bony compression.

Similarly, narrowing of the nasolacrimal ducts may lead to recurrent attacks of dacryocystitis. There is sclerosis with diaphyseal thickening of the appendicular skeleton giving a cylindrical appearance to the long bones. Metaphyseal involvement is minimal or absent, differentiating it from craniometaphyseal dysplasia. Similar manifestations may be found in the hands. The spine may be sclerotic.<sup>1,5,6,13-15</sup> Although the exact aetiology and pathogenesis of this disorder are unknown, a raised level of serum alkaline phosphatase suggests abnormal metabolic activity.<sup>1</sup> Histological and electron-microscopic examination of the bone in CDD has shown increased bone volume with defective calcification of the matrix. Interstitial calcification of skeletal muscle has also been found.<sup>12,16</sup>

The diagnosis of this disorder rests on the typical facial deformity and progressive nature of the bony abnormalities. Differential diagnoses include Camurati-Engelmann disease (diaphyseal dysplasia),<sup>17</sup> craniometaphyseal dysplasia, endosteal hyperostosis and other sclerosing bone disorders. Overlap syndromes have been identified and it is believed that CDD may be a 'group of diseases' rather than a single entity.<sup>6</sup> The management of this disorder is supportive and directed towards the treatment of complications. Decompressive and corrective craniofacial surgery has given disappointing results, and close observation is mandatory to detect recurrence of symptoms.<sup>1,9,10</sup> All forms of medical therapy, e.g. low-calcium diets, calcitriol therapy and other biochemical and hormonal manipulations, have failed to arrest the progress of the disorder.<sup>9,18</sup>

To date, stenosis of the spinal canal has not been described in CDD. At 47 years of age, our patient seemed to have outlived the complications that usually lead to early death in most cases. This could be because of a milder phenotypic expression. The pathology of stenosis of the spinal canal appears to be relentless hyperostosis with insufficient widening and remodelling of the spinal canal, resulting in uniform circumferential compression on the cord. The sclerotic process did not involve the soft tissues, as shown by the absence of ossification of the ligamentum flavum or any ectopic foci of calcification. In our view, the condition merited complete 'deroofing' of the cervical spinal canal to decompress the spinal cord, as any lesser procedure may have led to early recurrence of stenosis, caused by progressive hyperostosis. There were many problems associated with the surgery. Endotracheal intubation was very difficult; endoscopic laryngoscopy may be required.<sup>18</sup> In contrast to its nature in osteopetrosis, the bone is hard, and unyielding to the bone instruments commonly used in CDD. A high-speed burr (75 000 to 90 000 rev/min) was essential for safe decompression. Central laminectomy was

sufficient, as the compression was primarily midline without evidence of facet hypertrophy. Care should be taken to prevent mechanical trauma to the already compromised cord. Unfortunately, the cause of irrecoverable C5 and C6 root symptoms in our patient could not be ascertained, but inadvertent traction on the nerve roots during surgery may have occurred. In spite of the decompression, spasticity as a residual symptom may signify ischaemic damage to the spinal cord caused by chronic compression. The prognosis for neurological recovery thus remains guarded and may be related to the longstanding nature of the symptoms, the degree of hyperostosis and the ease of decompression.

No benefits in any form have been received or will be received from a commercial party related directly or indirectly to the subject of this article.

## References

1. Brueton LA, Winter RM. Craniodiaphyseal dysplasia. *J Med Genet* 1990;27:701-6.
2. Halliday J. A rare case of bone dystrophy. *British J Surgery* 1949;37:52-63.
3. Joseph R, Lefebvre J, Guy E, Job JC. Dysplasie craniodiaphysaire progressive: ses relations avec la dysplasie diaphysaire progressive de Camurati-Engelmann. *Ann Radiol* 1958;1:477-90.
4. Ghorlin RJ, Spranger J, Koszalka MF. Genetic craniotubular bone dysplasias and hyperostoses: a critical analysis. *Birth Defects* 1969;V:79-95.
5. Gemmel JH. Leontiasis ossea: a clinical and roentgenographic entity. *Radiology* 1935;25:723-9.
6. MacPherson RI. Craniodiaphyseal dysplasia: a disease or group of diseases? *J Can Assoc Radiol* 1974;25:22-33.
7. De Souza O. Leontiasis ossea case reports. *Porto Alegre Fac Med* 1927;13:46-54.
8. Schaefer B, Stein S, Oshman D, et al. Dominantly inherited craniodiaphyseal dysplasia: a new craniotubular dysplasia. *Clin Genet* 1986;30:381-91.
9. Richards A, Brain C, Dillon MJ, Bailey CM. Craniometaphyseal and craniodiaphyseal dysplasia, head and neck manifestations and management. *J Laryngol Otol* 1996;110:328-38.
10. Sinow JD, Gruss JS, Roberts TS, et al. Intracranial and extracranial reduction osteoplasty for craniodiaphyseal dysplasia: cleft palate. *Craniofac J* 1996;33:284-90.
11. Himi T, Igarashi M, Kataura A, Alford BR. Temporal bone findings in craniodiaphyseal dysplasia. *Auris, Nasus, Larynx* 1993;20:255-61.
12. McHugh DA, Rose GE, Garner A. Nasolacrimal obstruction and facial bone histopathology in craniodiaphyseal dysplasia. *Br J Ophthalmol* 1994;78:501-3.
13. Greenspan A. Sclerosing bone dysplasia: a target-site approach. *Skeletal Radiol* 1991;20:561-83.
14. Horan FT, Beighton PH. 'Osteopetrosis' in the Fairbank collection. *J Bone Joint Surg [Br]* 1978;60-B:53-5.
15. Tucker AS, Klein L, Antony GJ. Craniodiaphyseal dysplasia: evolution over a five year period. *Skeletal Radiology* 1976;1:47-53.
16. Beighton P, Cremin BJ. *Sclerosing bone dysplasias*. Berlin, Heidelberg: Springer-Verlag, 1980:125.
17. Sparkes RS, Graham CB. Camurati-Engelmann disease. *J of Medical Genetics* 1972;9:73-85.
18. Appleby JN, Bingham RM. Craniodiaphyseal dysplasia: another cause of difficult intubation. *Paediatr Anaesth* 1996;6:225-9.