



# Outcome of calf deep-vein thrombosis after total knee arthroplasty

C.-J. Wang, J.-W. Wang, L.-H. Weng, C.-C. Hsu, C.-F. Lo

From the Chang Gung Memorial Hospital, Kaohsiung, Taiwan

**We investigated the outcome of deep-vein thrombosis (DVT) in the calf after total knee arthroplasty (TKA) in 48 patients (45 women and three men) by clinical assessment and venographic study between three and four years after surgery. The mean age of the patients was  $67.2 \pm 7.7$  years (52 to 85) and the mean follow-up was  $42.6 \pm 2.7$  months (38 to 48). The diagnosis was osteoarthritis in 47 patients and rheumatoid arthritis in one patient. There were 44 calf thrombi, four popliteal thrombi but no thrombi in the femoral or iliac regions. Of the 48 patients, 24 were clinically symptomatic and 24 were asymptomatic. Clinical examination was carried out on 41 patients, of whom 37 underwent ascending venography. Seven were evaluated by telephone interview.**

**No patient had the symptoms or signs of recurrent DVT, venous insufficiency in the affected leg, or a history of pulmonary embolism. No patient had been treated for complications of their DVT. Thirty-six of the 37 venographic studies were negative for either old or new DVT in the affected leg. One patient had residual thrombi in the muscular branches of the veins.**

**Our study shows that deep-vein thromboses in the calf after TKA disappear spontaneously with time. No patient developed a recurrent DVT, proximal propagation or embolisation. Treatment of DVT in the calf after TKA should be based on the severity of the symptoms during the immediate postoperative period.**

*J Bone Joint Surg [Br] 2003;85-B:841-4.  
Received 16 December 2002; Accepted after revision 25 March 2003*

C.-J. Wang, MD, Clinical Professor  
J.-W. Wang, MD, Associate Professor  
L.-H. Weng, MD, Fellow  
C.-C. Hsu, MD, Fellow  
Department of Orthopaedic Surgery, Chang Gung Memorial Hospital,  
123 Ta-Pei Road, Niao-Sung Hsiang, Kaohsiung, Taiwan.

C.-F. Lo, MD, Medical Director  
Sanofi-Synthelabo Taiwan Ltd, 18F-6, 156, Min-sheng E. Road, Sec. 3,  
Taipei, Taiwan.

Correspondence should be sent to Professor C.-J. Wang.

©2003 British Editorial Society of Bone and Joint Surgery  
doi:10.1302/0301-620X.85B6.14096 \$2.00

Deep-vein thrombosis (DVT) after total knee arthroplasty (TKA) is common. Many studies have reported that a large thrombus proximal to the knee poses a higher risk of pulmonary embolism.<sup>1-8</sup> Others have shown that all thrombi can propagate into or above the popliteal vein despite early anticoagulation therapy and have recommended that prophylaxis should be targeted at the intraoperative and immediate postoperative periods.<sup>9</sup> The importance of DVT in the calf, however, is poorly understood and the treatment is controversial. Some studies have reported that the risks of treatment may be greater than those of the thrombosis itself.<sup>2,3,10</sup> The incidence of DVT after TKA is 84% in unprotected patients and may be as high as 68% in patients who receive prophylaxis for DVT.<sup>7</sup> There is controversy as to which pharmacological agent or form of mechanical prophylaxis should be used. Consequently, many issues concerning DVT are poorly understood, especially the duration of prophylaxis and the outcome of DVT in the calf. Our aim was to investigate the outcome of DVT in the calf after TKA between three and four years after surgery.

## Patients and Methods

In 1998 and 1999, a prospective clinical study with ascending venography was conducted at our institution in order to determine the incidence of DVT after TKA. The results showed that 55 (55 knees) of 102 (105 knees) patients had positive venographic findings for DVT, an incidence of 53%. Fifty-one (93%) of the thrombi were in the calf veins, four (7%) in the popliteal vein, and none in the femoral or iliac veins. There were no pulmonary emboli.

Our study was designed to assess the outcome of these thrombi between three and four years later. Seven patients were excluded; two had died from unrelated causes and five were lost to follow-up. The remaining 48 were available for assessment. There were 45 women and three men with a mean age of  $67.2 \pm 7.7$  years (52 to 85). Their mean body-weight was  $63.5 \pm 8.4$  kg (46 to 80.9), and their mean height was  $150.6 \pm 4.9$  cm (138 to 162). In 47 patients, the diagnosis was osteoarthritis and in one, rheumatoid arthritis. No DVT prophylaxis had been used at the time of operation. There were 44 DVTs in the calf veins, including the anterior and posterior tibial veins, the peroneal veins and muscular branches, four in the popliteal vein but none in the femoral

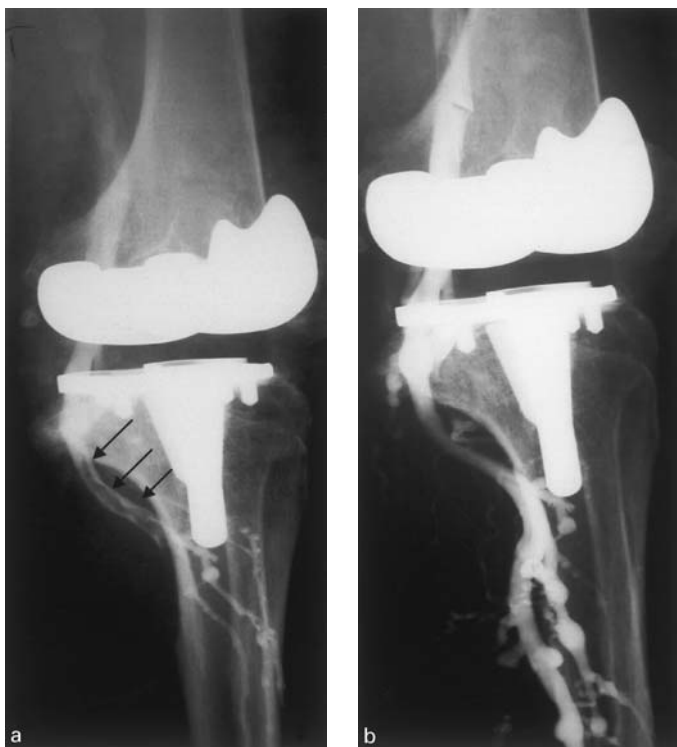

Fig. 1

Ascending venography of the left lower leg in a 67-year-old woman performed seven days after TKA. DVT of the popliteal vein can be seen (a, arrows). The leg was painful and swollen. Venography of the same leg undertaken 30 months after TKA showed no DVT. The original thrombus in the popliteal vein was absent and the venous blood flow of the leg was normal (b). There was neither pain nor swelling.

or iliac veins. There were no pulmonary emboli. Of the 48 patients, 24 were clinically symptomatic, and 24 were asymptomatic. The severity of the DVT was graded clinically as mild, moderate or severe. This grading was based on the degree of pain and swelling of the leg, tenderness of the calf, discoloration of the skin, enlargement of the circumference of the calf and thigh, Homan's sign and pyrexia. Of the 24 symptomatic patients, four were graded as severe and were treated with intravenous heparin (25000 units/day) for between three and five days until their symptoms improved. Thereafter they received aspirin (325 mg twice daily) for between eight and 12 weeks until their symptoms subsided. The remaining 20 patients developed mild to moderate symptoms and were treated with low-molecular-weight heparin (fraxiparine) for between three and seven days and then an analgesic, such as acetaminophen or codeine, for between eight and 12 weeks. The 24 patients with an asymptomatic DVT received no specific medication other than analgesics for TKA. All patients were reviewed regularly.

Of the 48 patients, 41 were examined clinically and seven were interviewed by telephone. The mean follow-up was  $42.5 \pm 2.7$  months (38 to 48). For most patients, the symptoms and signs of DVT subsided between three and six months after surgery. No patient developed a recurrent DVT and no patient had been treated for symptoms relating to the DVT in the affected leg. Ascending venography was carried out in the affected leg of 37 patients, and four refused venography. Two orthopaedic radiologists (C-CH and P-CY) who were blinded to the study interpreted the venographic results.

## Results

Six of the seven patients who were interviewed by telephone reported that the TKA was functioning well and there was no recurrent pain or swelling of the legs. One patient, with a history of chronic congestive heart failure, reported intermittent swelling of the legs after exercise. There was no pain or tenderness. Of the 41 patients who were examined clinically, five had had intermittent, mild, bilateral oedema and tenderness of the calf after exercise. These symptoms subsided completely within three to six months. Five patients with varicose veins showed no evidence of phlebitis. No patient had had symptoms or signs suggestive of a further DVT in the affected leg, or of pulmonary embolism.

Ascending venography was carried out in the affected legs of 37 patients, 36 of these were negative for either a new or old DVT (Fig. 1). One patient had residual thrombi in the muscular branches (Fig. 2). The DVTs which had been demonstrated in the initial venography included 33 in the calf and four in the popliteal veins. These were not found in the follow-up venographic studies. There was no patient with proximal propagation or embolisation, including pulmonary embolism. It thus appeared that DVTs in the calf after TKA resorb spontaneously without recurring and without associated pulmonary embolism.

## Discussion

DVT is common after TKA and may cause catastrophic complications, including fatal pulmonary embolism.<sup>11</sup> However, not all DVTs result in pulmonary embolism.<sup>3-5,12-16</sup>

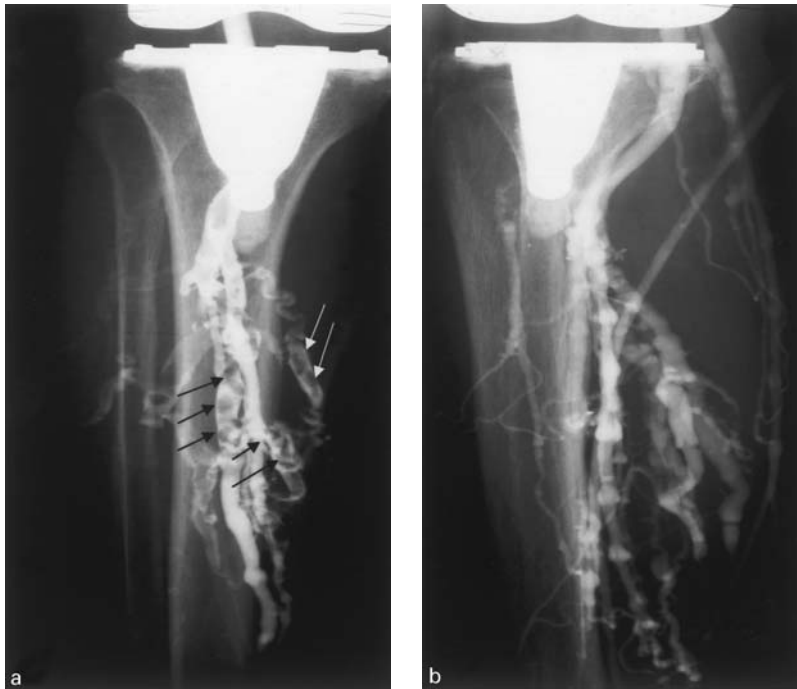


Fig. 2

Ascending venography of the left leg in a 71-year-old woman performed six days after TKA. Multiple deep-vein thrombi in the anterior and posterior tibial and peroneal veins, and the muscular branches can be seen (Fig. 2a, arrows). The leg was swollen and tender. Venography of the same leg undertaken 28 months after TKA showed residual thrombi in the muscular tranches, but no DVT in the anterior and posterior tibial and the peroneal veins (Fig. 2b). There was neither pain nor swelling.

Most studies report that patients with a proximal DVT are at a higher risk of pulmonary embolism,<sup>2,5,6,17</sup> although the clinical significance of a DVT in the calf remains controversial.<sup>1,4,6,9,10,13,14,17,18</sup> Many studies have reported that some form of prophylaxis, including anticoagulation therapy with low-molecular-weight heparin in the early postoperative period, has been effective in reducing the incidence of DVT. None has shown an ability totally to prevent a DVT.<sup>1,3,7-9,19-24</sup> Some forms of DVT may carry a lower risk of pulmonary embolism. Identification of this patient population may provide guidelines for selecting which patients should be exposed to the risks of anticoagulation therapy.<sup>6,17</sup>

The incidence of DVT, as shown on venography after TKA in an Asian population, is similar to that of a Western population.<sup>14,15,19,25-28</sup> However, there are differences. Reports have shown that the rate of proximal DVT in the Asian population is very low (4.4%) without pulmonary embolism.<sup>27</sup> There may, therefore, be an inherent difference between Asian and Western populations, although current data are insufficient to reach a conclusion.

Several studies from Western countries have reported conflicting opinions on the significance of a calf DVT and its relationship to pulmonary embolism.<sup>2,4,5,12,29,30</sup> It has been reported that local haemodynamic alterations resulting from undertaking a TKA create an environment which is conducive to the development of an acute DVT. All thromboses, especially those over 5 mm in size can propagate into, or beyond, the popliteal vein and potential cause of pulmonary embolism.<sup>9,17,18</sup> Some studies have reported that calf DVTs are associated with a higher rate of fatal emboli,<sup>2,5</sup> although others have shown a low incidence of pulmonary embolism associated with a calf DVT after TKA.<sup>4,12,29,30</sup> It has also

been said that thrombi in the calf are securely attached and may resolve spontaneously, and also they are too small to cause symptoms if they embolise.<sup>6,12,17</sup> The results of our current study support the view that DVTs in the calf in an Asian population dissolve spontaneously with time. No proximal propagation or embolisation was seen. Our study does not show the fate of a proximal DVT because none of our patients had a proximal DVT in either the femoral or iliac vein.

Many studies have reported that patients with a prior history of DVT are at an increased risk of developing a recurrence.<sup>3,4,7,8,17,23,29-31</sup> Other studies have also reported an association between DVT and risk factors such as age, gender, obesity, varicosities, hypertension, immobilisation, tourniquet time and the use of bone cement.<sup>13,24,27</sup> However, the data presented in this study did not show an association between recurrent DVT and such risk factors after between three and four years.

In conclusion, a DVT in the calf after TKA can resorb spontaneously with time. We observed neither proximal propagation nor embolisation. The treatment of a symptomatic DVT in the calf should be based upon the severity of the symptoms at the time of presentation in the early post-operative period.

No benefits in any form have been received or will be received from a commercial party related directly or indirectly to the subject of this article.

## References

1. Francis CW, Pellegrini VD, Stulberg BN, et al. Prevention of venous thrombosis after total knee arthroplasty: comparison of antithrombin III and low-dose heparin with dextran. *J Bone Joint Surg [Am]* 1990;72-A:976-82.
2. Giachino A. Relationship between deep-vein thrombosis in the calf and fatal pulmonary embolism. *Can J Surg* 1988;31:129-30.

3. **Lotke PA, Ecker ML, Alavi A, Berkowitz H.** Indications for the treatment of deep venous thrombosis following total knee replacement. *J Bone Joint Surg [Am]* 1984;66-A:202-8.
4. **Lotke PA, Steinberg ME, Ecker ML.** Significance of deep venous thrombosis in the lower extremity after total joint arthroplasty. *Clin Orthop* 1994;299:25-30.
5. **Lotke PA, Wong RY, Ecker ML.** Asymptomatic pulmonary embolism after total knee replacement. *Orthop Trans* 1986;10:490.
6. **Moser KM, LeMoine JR.** Is embolic risk conditioned by location of deep venous thrombosis? *Ann Intern Med* 1981;94:439-44.
7. **Sculco TP.** Establishing a universal protocol for deep vein thrombosis following orthopedic surgery: total knee arthroplasty. *Orthopedics* 1996;19:6-8 (suppl).
8. **Stulberg BN, Insall JN, Williams GW, Ghelman B.** Deep-vein thrombosis following total knee replacement: an analysis of six hundred and thirty-eight arthroplasties. *J Bone Joint Surg [Am]* 1984;66-A:194-201.
9. **Maynard MJ, Sculco TP, Ghelman B.** Progression and regression of deep vein thrombosis after total knee arthroplasty. *Clin Orthop* 1991;273:125-30.
10. **Francis CW, Ricotta JJ, Evarts CM, Marder VJ.** Long-term clinical observations and venous functional abnormalities after asymptomatic venous thrombosis following total hip or knee arthroplasty. *Clin Orthop* 1988;232:271-8.
11. **Robinson KS, Anderson DR, Gross M, et al.** Accuracy of screening compression ultrasonography and clinical examination for the diagnosis of deep vein thrombosis after total hip or knee arthroplasty. *Canadian J Surg* 1998;41:368-73.
12. **Kim YH, Kim JS.** Incidence and natural history of deep-vein thrombosis after total knee arthroplasty: a prospective, randomised study. *J Bone Joint Surg [Br]* 2002;84-B:566-70.
13. **Kim YH, Kim VE.** Factors leading to low incidence of deep vein thrombosis after cementless and cemented total knee arthroplasty. *Clin Orthop* 1991;273:119-24.
14. **Kim YH, Suh JS.** Low incidence of deep-vein thrombosis after cementless total hip replacement. *J Bone Joint Surg [Am]* 1988;70-A:878-82.
15. **Kim YH.** The incidence of deep vein thrombosis after cementless and cemented knee replacements. *J Bone Joint Surg [Br]* 1990;72-B:779-83.
16. **Leutz DW, Stauffer ES.** Color duplex Doppler ultrasound scanning for detection of deep venous thrombosis in total knee and hip arthroplasty patients: incidence, location, and diagnostic accuracy compared with ascending venography. *J Arthroplasty* 1994;9:543-8.
17. **Kakkar VV, Howe CT, Flanc C, Clarke MB.** Natural history of post-operative deep-vein thrombosis. *Lancet* 1969;2:230-2.
18. **Doouss TW.** The clinical significance of venous thrombosis of the calf. *Br J Surg* 1976;63:377-8.
19. **Fong YK, Ruban P, Yeo SJ, et al.** Use of low molecular weight heparin for prevention of deep vein thrombosis in total knee arthroplasty: a study of its efficacy in an Asian population. *Ann Academy Medicine Singapore* 2002;29:439-41.
20. **Hodge WA.** Prevention of deep vein thrombosis after total knee arthroplasty: Coumarin versus pneumatic calf compression. *Clin Orthop* 1991;271:101-5.
21. **McKenna R, Galante J, Bachmann F, et al.** Prevention of venous thromboembolism after total knee replacement by high-dose aspirin or intermittent calf and thigh compression. *Br Med J* 1980;280:514-7.
22. **Merli GJ.** Duration of deep vein thrombosis and pulmonary embolism prophylaxis after joint arthroplasty. *Med Clin North Am* 2001;85:1101-7.
23. **Miric A, Lombardi P, Sculco TP.** Deep vein thrombosis prophylaxis: a comprehensive approach for total hip and total knee arthroplasty patient population. *Am J Orthop* 2000;29:269-74.
24. **Sharrock NE, Haas Sb, Hargett MJ, et al.** Effects of epidural anesthesia on the incidence of deep-vein thrombosis after total knee arthroplasty. *J Bone Joint Surg [Am]* 1991;73-A:502-6.
25. **Rabinov K, Paulin S.** Roentgen diagnosis of venous thrombosis in the leg. *Arch Surg* 1972;104:134-64.
26. **Rossi R, Agnelli G.** Current role of venography in the diagnosis of deep-vein thrombosis. *Minerva Cardioangiologica* 1998;46:507-14.
27. **Wang CJ, Wang JW, Chen LM, et al.** Deep vein thrombosis after total knee arthroplasty. *J Formosan Med Ass* 2000;99:848-53.
28. **Yang LC, Wang CJ, Lee TH, et al.** Early diagnosis of deep vein thrombosis in female patients who undergo total knee arthroplasty with measurement of P-selectin activation. *J Vasc Surg* 2002;35:707-12.
29. **Ansari S, Warwick D, Ackroyd CE, Newman JH.** Incidence of fatal pulmonary embolism after 1390 knee arthroplasties without routine prophylactic anticoagulation, except in high-risk cases. *J Arthroplasty* 1997;12:599-602.
30. **Hanel KC, Abbott WM, Reidy NC, et al.** The role of two noninvasive tests in deep venous thrombosis. *Ann Surg* 1981;194:725-30.
31. **McKenna R, Bachmann F, Kaushal SP, Galante JO.** Thromboembolic disease in patients undergoing total knee replacement. *J Bone Joint Surg [Am]* 1976;58-A:928-32.